

## CLINICAL VIGNETTE

# Community Acquired, Native Valve Endocarditis with *Staphylococcus epidermidis*

Peter Young, MD, Lisle A. Winston, MD and Daniel P. Stefanko, MD, PhD

### Case Presentation

A 72-year-old man presented to the clinic with 3 weeks of worsening lower extremity edema, fatigue, and a blotchy, red rash on his legs. He had no fever, chills, chest pain, dyspnea, cough, or weight changes. Past medical history includes hypertension, hyperlipidemia, and essential tremor. He was previously physically active and did not smoke or use drugs. He recently traveled to Mexico but noted the symptoms began prior to departure. A few weeks prior to his illness onset he fell with mild abrasions to his lower extremities which have healed.

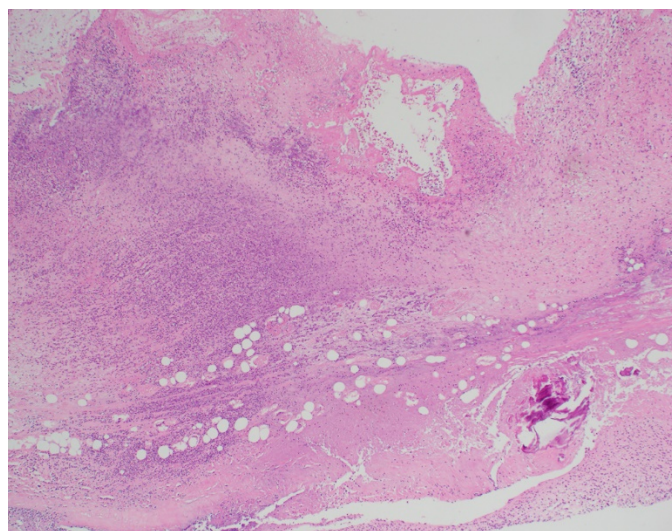
Physical exam included normal vitals: temperature of 36.4°C, pulse of 59 beats/min, blood pressure of 108/38 mm Hg, and respiratory rate of 18/min. Room air oxygen saturation was 97%. He was in no distress. There was no jugular venous distension and no dental disease. Pulmonary examination was unremarkable. Cardiac auscultation revealed a III/VI diastolic murmur at the left lower sternal border. Extremities were notable for 2+ pitting edema below the knees. Skin exam showed blanching erythematous patches over the lower legs with several small healing abrasions. There were no splinter hemorrhages, Janeway lesions, or Osler's nodes. The remainder of the physical exam was unremarkable.

An electrocardiogram showed sinus bradycardia and new prolonged PR interval of 276 milliseconds ( $N < 200$ ). Complete blood count and comprehensive metabolic panel were within normal limits. C-reactive protein was elevated 3.2 mg/dL (normal range  $< 0.8$  mg/dL), erythrocyte sedimentation rate was 12 mm/hr ( $\leq 12$  mm/hr) and brain natriuretic peptide was 247 pg/mL ( $< 100$  pg/mL). Chest imaging was unremarkable. Transthoracic echocardiogram showed mild concentric left ventricular hypertrophy, a severely dilated left atrium, and moderate aortic regurgitation with a tri-leaflet, thickened, and sclerotic aortic valve. Pulmonary artery systolic pressure was 40 mm Hg. There were no valvular vegetations. No prior echocardiographic images were available for comparison. Bilateral lower extremity dopplers were negative for deep venous thrombosis.

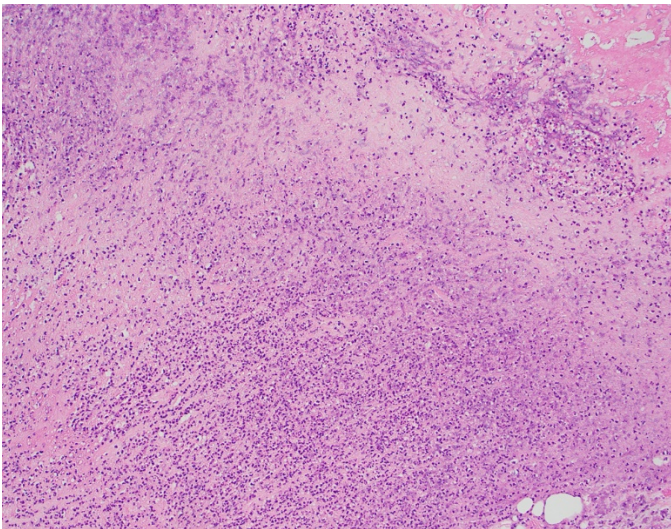
24-hours later, 2 of 2 blood cultures returned positive for Gram positive cocci in clusters. He was admitted to the hospital and started on intravenous Vancomycin. Blood cultures speciated as methicillin-sensitive *Staphylococcus epidermidis* and he was transitioned to intravenous Cefazolin.

A transesophageal echocardiogram showed a 5 x 5 mm echodensity on the ventricular surface of the noncoronary cusp of the aortic valve, without aortic root abscess. After his blood cultures were negative for 48 hours on antibiotics, he was taken for urgent aortic valve replacement. Operating room findings were notable for complete and total destruction of the non-coronary aortic valve leaflet. Valve leaflets were sent for pathology and showed active endocarditis with variably sized fragmented vegetations, both detached and adherent to the aortic valve leaflet. Histologically they showed prominent acute inflammation, fibrin deposition, foci of necrosis, and numerous Gram positive cocci (confirmed by Gram and GMS stains) in a background of calcific degeneration.

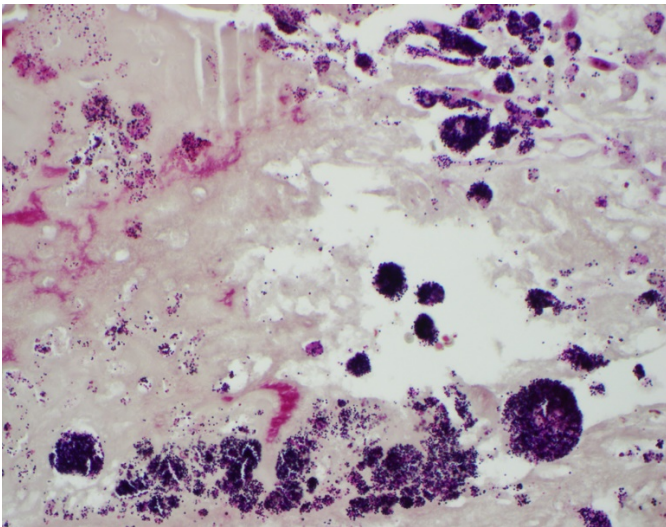
He was discharged from the hospital on a 6-week course of intravenous Cefazolin. The operating room and pathology findings were concerning for persistent infection of the valvular bed, and after completing IV antibiotics, he received a prolonged course of oral Cephalexin.



**Figure 1:** Low power view of aortic valve vegetation with fibrin deposition, necrosis, extensive neutrophilic inflammatory infiltrate, and focal calcification, H&E (Hematoxylin and Eosin) stain at 40x



**Figure 2:** High power view of aortic valve vegetation with basophilic necrosis, fibrin deposition (top right), and extensive neutrophilic inflammatory infiltrate H&E stain at 400x



**Figure 3:** Gram stain highlighting numerous variably sized clusters of Gram positive cocci in association with aortic valve vegetation, 400x

### Discussion

Coagulase-negative staphylococci (CoNS) species such as *Staphylococcus epidermidis* are a rare but increasing cause of native valve infectious endocarditis. Compared to prosthetic valve infections, native valve infective endocarditis is more likely to occur in older patients over 60 years with underlying structural heart disease. Male patients and patients with indwelling vascular catheters or devices are also at higher risk.<sup>1</sup> We describe a previously healthy 72-year-old man with subacute *Staphylococcus epidermidis* endocarditis of his aortic valve. This case illustrates the sometimes indolent and protean presentations of CoNS endocarditis.

In a large case series of 2781 patients with native valve endocarditis, 11% of cases were due to CoNS. Forty percent of these

were due to healthcare associated bacteremia compared to 60% community-associated.<sup>1,2</sup> Historical reports note approximately 50% of cases of infective endocarditis involved a valvular lesion from rheumatic heart disease. Modern case series report rheumatic heart disease is a factor in fewer than 5% of cases. Healthcare exposure is a greater risk factor in 25% of cases.<sup>1</sup> Currently, approximately 55% of native valve endocarditis cases are due to degenerative (non-rheumatic) valvular disease in older patients with a larger number of medical comorbidities.<sup>3</sup>

As in this case, CoNS infections can be subacute to chronic with non-specific and sometimes mild symptoms and subtle clinical signs.<sup>4</sup> Despite its more indolent course and historical classification as a “low-virulence” organism, CoNS infective endocarditis is associated with high rates of heart failure, cardiac surgery, and mortality.<sup>2</sup> A 2009 case series compared *Strep viridans* and *Staph aureus*, and CoNS endocarditis had the highest rates of heart failure (49%), need for cardiac surgery (54%), as well as in hospital mortality (19%).<sup>2</sup> This may partially be explained by a greater association of CoNS infections with significant medical comorbidities. The organism also has ability to form a biofilm which remains undetected over a prolonged period of time.<sup>4</sup> These biofilms can form on indwelling devices and catheters as well as structurally abnormal heart valves. Skin and mucous membrane colonization is common and breaches through trauma or invasive procedures are a frequent route of infection.<sup>4</sup> We suspect that this patient had subclinical calcification of his aortic valve, which was seeded by transient CoNS bacteremia from his lower extremity wounds.

Treatment of native valve infective endocarditis can be as long as 6 weeks, particularly with left-sided valve lesions which tend to have higher bacterial density.<sup>5</sup> Outpatient follow up with cardiology and infectious disease is crucial. Early valve surgery – as in this case – should be considered for patients with left sided native valve infective endocarditis who present with valvular dysfunction, as well as persistent bacteremia beyond 5-7 days of appropriate antibiotics, heart block and abscesses or destructive lesions, recurrent embolic events, large mobile lesions (> 10mm), or infection with fungi or highly resistant organisms.<sup>5</sup> Most CoNS is methicillin-resistant, though this patient’s infection was methicillin-sensitive and treated with IV Cefazolin. Based on surgical pathology showing persistent infection of his valvular bed, his outpatient infectious disease physician recommended a prolonged course of oral antibiotics after finishing 6 weeks of IV antibiotics.

### REFERENCES

1. Murdoch DR, Corey GR, Hoen B, Miró JM, Fowler VG Jr, Bayer AS, Karchmer AW, Olaison L, Pappas PA, Moreillon P, Chambers ST, Chu VH, Falcó V, Holland DJ, Jones P, Klein JL, Raymond NJ, Read KM, Tripodi MF, Utili R, Wang A, Woods CW, Cabell CH; International Collaboration on Endocarditis-Prospective Cohort Study (ICE-PCS) Investigators.

Clinical presentation, etiology, and outcome of infective endocarditis in the 21st century: the International Collaboration on Endocarditis-Prospective Cohort Study. *Arch Intern Med.* 2009 Mar 9;169(5):463-73. doi: 10.1001/archinternmed.2008.603. PMID: 19273776; PMCID: PMC3625651.

2. **Chu VH, Cabell CH, Abrutyn E, Corey GR, Hoen B, Miro JM, Olaison L, Stryjewski ME, Pappas P, Anstrom KJ, Eykyn S, Habib G, Benito N, Fowler VG Jr; International Collaboration on Endocarditis Merged Database Study Group.** Native valve endocarditis due to coagulase-negative staphylococci: report of 99 episodes from the International Collaboration on Endocarditis Merged Database. *Clin Infect Dis.* 2004 Nov 15;39(10):1527-30. doi: 10.1086/424878. Epub 2004 Oct 27. PMID: 15546091.
3. **Hill EE, Herijgers P, Claus P, Vanderschueren S, Herregods MC, Peetermans WE.** Infective endocarditis: changing epidemiology and predictors of 6-month mortality: a prospective cohort study. *Eur Heart J.* 2007 Jan;28(2):196-203. doi: 10.1093/eurheartj/ehl427. Epub 2006 Dec 7. PMID: 17158121.
4. **Becker K, Heilmann C, Peters G.** Coagulase-negative staphylococci. *Clin Microbiol Rev.* 2014 Oct;27(4):870-926. doi: 10.1128/CMR.00109-13. PMID: 25278577; PMCID: PMC4187637.
5. **Baddour LM, Wilson WR, Bayer AS, Fowler VG Jr, Tleyjeh IM, Rybak MJ, Barsic B, Lockhart PB, Gewitz MH, Levison ME, Bolger AF, Steckelberg JM, Baltimore RS, Fink AM, O'Gara P, Taubert KA; American Heart Association Committee on Rheumatic Fever, Endocarditis, and Kawasaki Disease of the Council on Cardiovascular Disease in the Young, Council on Clinical Cardiology, Council on Cardiovascular Surgery and Anesthesia, and Stroke Council.** Infective Endocarditis in Adults: Diagnosis, Antimicrobial Therapy, and Management of Complications: A Scientific Statement for Healthcare Professionals From the American Heart Association. *Circulation.* 2015 Oct 13;132(15):1435-86. doi: 10.1161/CIR.0000000000000296. Epub 2015 Sep 15. Erratum in: *Circulation.* 2015 Oct 27;132(17):e215. doi: 10.1161/CIR.0000000000000332. Erratum in: *Circulation.* 2016 Aug 23;134(8):e113. doi: 10.1161/CIR.0000000000000427. Erratum in: *Circulation.* 2018 Jul 31;138(5):e78-e79. doi: 10.1161/CIR.0000000000000594. PMID: 26373316.