

## CLINICAL VIGNETTE

---

# Peritoneal Lymphomatosis: A Rare Presentation and Diagnostic Challenge in an 82-Year-Old Male

---

Eric J. Kwoh, MD and Jonathan Helali, MD

An 82-year-old male with follicular lymphoma in remission status post chemotherapy and localized left renal cell carcinoma post remote partial nephrectomy in 2011 presented to the Emergency Department with increased fatigue, shortness of breath, and abdominal distension. Symptoms were noted two months ago and significantly worsened over the past week. He now had to rest after walking less than half a block and reported occasional drenching night sweats as well as unintentional weight loss. He denied any fevers, chest pain or cough.

On arrival to the Emergency Department (ED), vital signs were within normal limits. Physical exam revealed a well-appearing male with a large, soft, nontender distended abdomen without guarding or rebound. Cardiopulmonary exam was unremarkable except for moderate pitting edema to his bilateral shins. Laboratory studies were notable for a blood urea nitrogen of 42 mg/dL, increased serum creatinine of 2.36 mg/dL (from 1.1 baseline), a hemoglobin of 11.9 g/dL, and a hematocrit of 37.0%. LDH was mildly elevated at 349 U/L and BNP and TSH were unremarkable. ECG was normal. CXR revealed only a small right pleural effusion. Non-contrast computed tomography (CT) scan of the abdomen revealed a large mass in the retroperitoneum measuring 10 x 11 cm, appearing as a large conglomerate of adenopathy (see Figure 1). This mass involved the left ureter, with moderate-to-severe left-sided hydronephrosis (see Figure 2). A moderate amount of ascites was noted in addition to diffuse omental nodularity, omental caking, and soft tissue thickening (see Figure 2).

The patient was admitted to the General Medicine service for expedited evaluation of suspected malignancy with associated peritoneal carcinomatosis (PC), and obstructive nephropathy. Urology recommended a trial of isotonic fluids prior to placement of a percutaneous nephrostomy tube for decompression. Hematology Oncology recommended biopsy of the retroperitoneal mass, and advised of the possibility the retroperitoneal mass could represent aggressive lymphoma given prior follicular lymphoma. However, they believed lymphoma would be less likely to present with extensive abdominal disease which included significant omental caking, nodularity, and likely malignant ascites. Given patient's history of renal cell carcinoma, a solid gastrointestinal tumor with associated peritoneal carcinomatosis was also strongly considered.

After admission, the patient's renal function improved, and nephrostomy tube placement was deferred. While awaiting biopsy of the retroperitoneal mass, patient tested positive for

COVID-19. He denied shortness of breath and other symptoms other than a mild headache. After completion of remdesivir treatment, he underwent biopsy of the retroperitoneal mass via interventional radiology and was discharged with hematology-oncology follow up. At follow-up, pathology results revealed diffuse large B-cell lymphoma. Hematology Oncology thought the new lymphoma diagnosis likely represented transformation from prior diagnosis of follicular lymphoma. His initial symptoms and radiographic findings of omental caking, nodularity, and malignant ascites were consistent with peritoneal lymphomatosis. The patient started 6 planned cycles of attenuated chemotherapy of rituximab, cyclophosphamide, doxorubicin, vincristine, and prednisolone (R-miniCHOP).

### Discussion

Approximately 40% of lymphomas have extra-nodal involvement.<sup>1</sup> Peritoneal lymphomatosis (PL) is an extremely rare presentation of extra-nodal lymphoma involvement, characterized by diffuse intra-abdominal peritoneal dissemination. It is usually associated with high-grade lymphomas such as diffuse large B-cell lymphoma (DLBCL) and Burkitt's lymphoma.<sup>2</sup> Most patients complain of non-specific abdominal pain, distension, and weight loss.<sup>3</sup> Peritoneal lymphomatosis may be mistaken for the more common peritoneal carcinomatosis (PC). Both appear very similar on imaging and usually cannot be distinguished solely on imaging.<sup>4</sup> CT or MRI findings of PL generally include peritoneal enhancement or peritoneal thickening, omental caking, and ascites, in addition to findings of a primary lymphoma elsewhere. Because imaging findings cannot reliably distinguish PC from other peritoneal diseases and ascitic fluid is not generally sensitive for malignancy, a definitive diagnosis may require laparoscopic biopsy.<sup>5</sup> In our patient, the prior diagnosis of DLBCL suggested the patient's peritoneal disease was due to peritoneal lymphomatosis and precluded need for additional biopsies.

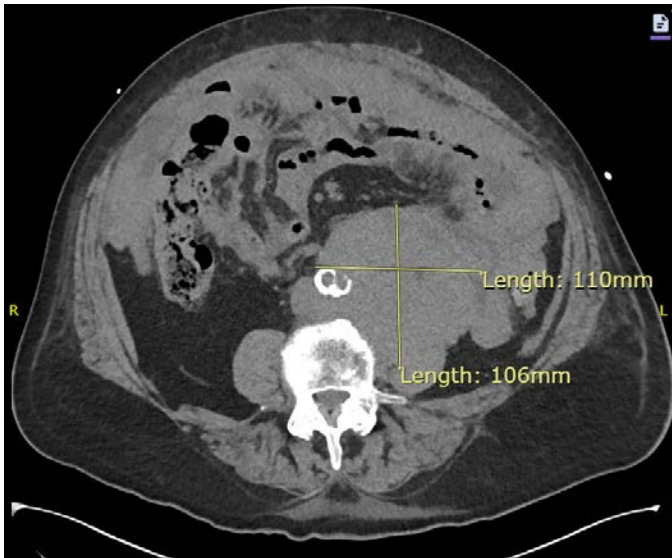
It is important to distinguish PL from other intra-peritoneal diseases, as prognosis and management differ significantly.<sup>6</sup> Peritoneal lymphomatosis is treated non-surgically and may respond well to chemotherapy. PC often requires more aggressive treatment with cytoreductive surgery and intraperitoneal chemotherapy.<sup>7</sup> Twenty-five percent of patients with PL were reported to have a good response to chemotherapy. If left untreated, the median survival is less than 1 year.<sup>8,9</sup>

There are several case reports of PL with delayed diagnosis given radiographic similarities to peritoneal carcinomatosis.<sup>2,6,10</sup> In our patient, his history of a low-grade follicular lymphoma initially presented a quandary interpreting presence of significant peritoneal disease on CT imaging. If this was a recurrence of his follicular lymphoma, peritoneal lymphomatosis would be a highly unlikely association with a low-grade lymphoma, although rare cases have been reported.<sup>11</sup> Thus, a transformation to a high-grade lymphoma with associated PL, or a new solid tumor with associated PC also needed to be considered in the differential. While PL can be responsive to chemotherapy, it is considered an aggressive histological subtype of a high-grade lymphoma with potential rapid progression. Burkitt lymphoma has been shown to double within 24 hours.<sup>12</sup> Prompt recognition and early diagnosis is needed.

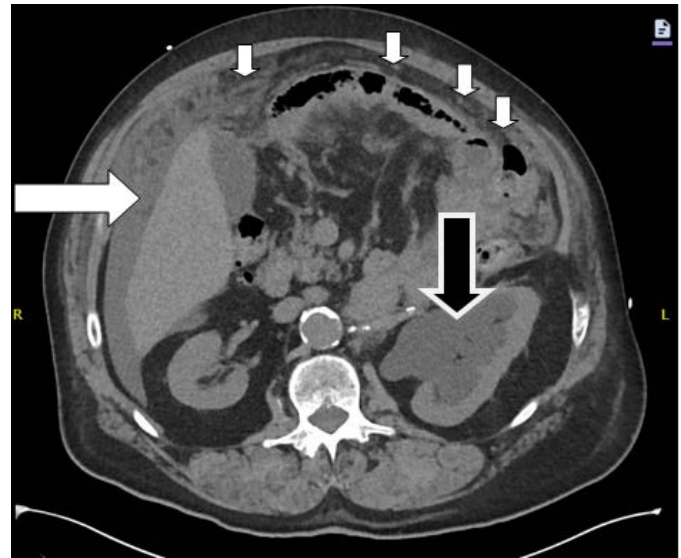
### Conclusion

Peritoneal lymphomatosis is a rare presentation of extra-nodal involvement of high-grade lymphoma. Peritoneal lymphomatosis is generally treated non-surgically and may respond well to chemotherapy. This continues to be a diagnostic challenge given similar symptoms and radiographic characteristics to peritoneal carcinomatosis. It is important to distinguish between these two diseases as prognosis and management differ significantly.

### Figures



**Figure 1.** Non-contrast CT scan of abdomen showing a large retroperitoneal mass that measures 110 mm by 106 mm.



**Figure 2.** Non-contrast CT scan of abdomen demonstrating severe left sided hydronephrosis (large black arrow), significant peritoneal thickening with nodularity (small white arrows), and perihepatic ascites (large white arrow).

### REFERENCES

1. **Lee WK, Lau EW, Duddalwar VA, Stanley AJ, Ho YY.** Abdominal manifestations of extranodal lymphoma: spectrum of imaging findings. *AJR Am J Roentgenol.* 2008 Jul;191(1):198-206. doi: 10.2214/AJR.07.3146. PMID: 18562746.
2. **Weng SC, Wu CY.** Lymphoma presenting as peritoneal lymphomatosis with ascites. *J Chin Med Assoc.* 2008 Dec;71(12):646-50. doi: 10.1016/S1726-4901(09)70009-7. PMID: 19114331.
3. **Flores E, Aydin N, Vu D, Misra S.** A Case Series of diffuse large B-cell lymphoma and burkitt lymphoma presenting with peritoneal lymphomatosis. *Int J Surg Case Rep.* 2016;28:262-265. doi: 10.1016/j.ijscr.2016.10.007. Epub 2016 Oct 8. PMID: 27756028; PMCID: PMC5067294.
4. **Kim YG, Baek JY, Kim SY, Lee DH, Park WS, Kwon Y, Kim MJ, Kang J, Lee JM.** Peritoneal lymphomatosis confounded by prior history of colon cancer: a case report. *BMC Cancer.* 2011 Jun 27;11:276. doi: 10.1186/1471-2407-11-276. PMID: 21708008; PMCID: PMC3141780.
5. **Mito M, Fukunari H, Watanabe A, Hayashi T.** [A Case of Peritoneal Lymphomatosis Diagnosed by Laparoscopic Biopsy]. *Gan To Kagaku Ryoho.* 2020 Dec;47(13):1792-1794. Japanese. PMID: 33468831.
6. **Shaikh DH, Gongati S, Salman SH, Reyes OA, Chilimuri S.** Peritoneal Lymphomatosis: The Great Mimicker. *Cureus.* 2021 Apr 15;13(4):e14508. doi: 10.7759/cureus.14508. PMID: 34007761; PMCID: PMC8121203.
7. **Szadkowska MA, Palucki J, Cieszanowski A.** Diagnosis and treatment of peritoneal carcinomatosis - a comprehensive overview. *Pol J Radiol.* 2023 Feb

9;88:e89-e97. doi: 10.5114/pjr.2023.125027. PMID: 36910885; PMCID: PMC9995246.

8. **Ravindranath A, Srivastava A, Seetharaman J, Pandey R, Sarma MS, Poddar U, Yachha SK.** Peritoneal Lymphomatosis Masquerading as Pyoperitoneum in a Teenage Boy. *ACG Case Rep J.* 2019 Jun 17;6(6):e00116. doi: 10.14309/crj.000000000000116. PMID: 31616776; PMCID: PMC6722330.
9. **Zhu M, Wu Z, Yang Z, Ning B, Yu S, Gu X, Yu H.** Non-Hodgkin's Lymphoma Presenting as Isolated Peritoneal Lymphomatosis: A Case Report and Literature Review. *Front Oncol.* 2021 Sep 2;11:719554. doi: 10.3389/fonc.2021.719554. PMID: 34540689; PMCID: PMC8443791.
10. **Horger M, Müller-Schimpfle M, Yirkin I, Wehrmann M, Claussen CD.** Extensive peritoneal and omental lymphomatosis with raised CA 125 mimicking carcinomatosis: CT and intraoperative findings. *Br J Radiol.* 2004 Jan;77(913):71-3. doi: 10.1259/bjr/35139284. PMID: 14988144.
11. **Cunningham N, Ffrench-Constant S, Planche K, Gillmore R.** Peritoneal lymphomatosis: a rare presentation of follicular lymphoma mimicking peritoneal carcinomatosis. *BMJ Case Rep.* 2015 Feb 18;2015:bcr2014207136. doi: 10.1136/bcr-2014-207136. PMID: 25694630; PMCID: PMC4336898.
12. **Turro J, Singh P, Sarao MS, Tadepalli S, Cheriya P.** Adult Burkitt lymphoma- an Island between lymphomas and leukemias. *J Community Hosp Intern Med Perspect.* 2019 Feb 11;9(1):25-28. doi: 10.1080/20009666.2019.1574545. PMID: 30788071; PMCID: PMC6374956.