

CLINICAL VIGNETTE

Severe Hypothyroidism Requiring High Flow Nasal Oxygen

Samantha Garcia, MS¹, Kirstin Peters, MD² and Huy Phan, MD³

¹David Geffen School of Medicine at UCLA, Los Angeles, California

²UCLA Internal Medicine Residency Program, Los Angeles, CA

³Department of Medicine, Olive View-UCLA Medical Center, Sylmar, California

Case Presentation

A 32-year-old man presented with progressive shortness of breath, fatigue, and lower extremity stiffness and myalgias. His symptoms began two years prior and had drastically worsened over the last month. He reported shortness of breath at rest which worsened during exertion. He also noted lower extremity stiffness and myalgias making it difficult to bend his legs. Other symptoms included weight gain, hair loss, and slowing of motor activity. His mother reported physical changes starting five months prior including facial and extremity swelling. She also reported that the patient had increasing difficulty speaking with excessive drooling and lip swelling, as well as, very dry skin and decreased energy. These changes prompted the family to bring the patient to the emergency department for further evaluation. The patient denied constipation, cold intolerance, chest pain, fever, recent illness and had no history of recent travel or sick contacts. His past medical history included congenital hypothyroidism, previously well-controlled on levothyroxine. However, after loss of insurance coverage, he stopped taking levothyroxine two years ago.

On examination, the patient was afebrile with BP of 110/76 mmHg, heart rate of 81 beats/minute, respiratory rate of 21 breath/minute, body mass index of 41, and oxygen saturation of 82% on room air that improved to 94-98% on 8 l/min of oxygen. Physical exam was notable for obesity, low-pitched hoarse voice, diffuse facial and neck edema, swollen lips, prominent macroglossia, scalp hair thinning, and dry, flaky skin throughout his body (Figures 1-3). His skin was cool to touch, and he had bilateral, non-pitting pretibial edema. Lungs were clear to auscultation bilaterally. Thyroid was without enlargement or nodules. Admission labs were remarkable for creatinine kinase (CK) 3,600 units/L, thyroid stimulating hormone (TSH) of 144.37 uIU/mL and a free T4 <0.40 ng/dL. Venous blood gas (VBG) revealed pH = 7.27, pCO₂ = 82 mmHg. Basic metabolic panel was notable for a bicarbonate level of 36. Complete blood count and chest x-ray were unremarkable (Figure 4).

On admission, Pulmonology and Endocrinology consulted. He was placed on bilevel positive airway pressure (BiPAP) overnight and started on intravenous levothyroxine. His VBGs and thyroid markers slowly improved, however, on day five of admission, oxygen saturation decreased despite high flow nasal cannula (HFNC) and use of a non-rebreather mask. An arterial

blood gas revealed an alveolar-arterial (A-a) gradient of 400, pH 7.37, pCO₂ 65 mmHg, and pO₂ 58 mmHg. He was re-evaluated and transferred to the intensive care unit (ICU). He required up to 60 l/min of oxygen at FIO₂ of 100%.

In the ICU, a chest x-ray (Figure 5) and CT thorax with contrast showed possible volume overload versus atelectasis, without evidence of infection. He was given intravenous furosemide and empiric antibiotics for community acquired pneumonia. His increased A-a gradient, there were concerns for shunting. However, an echocardiogram was unremarkable and bilateral lower extremity venous duplex ultrasounds and d-dimer were negative.

In the ICU, the patient's respiratory status improved with nightly BiPAP 16/8 FiO₂ 50%, simple face mask during the day, and continued treatment with intravenous levothyroxine. The patient was transferred from the ICU on supplemental face mask oxygen on hospital day 12 and discharge on hospital day 21 on 4 l/min of nasal cannula oxygen. At discharge, the patient's presenting physical exam findings had drastically improved (Figures 1-3). TSH prior to discharge was 12.3 uIU/mL with free T4 of 1.55 ng/dL. He was discharged with nightly home average volume-assured pressure support (AVAPS), 3 liters of home oxygen, and daily oral levothyroxine of 175 mcg.

The patient was seen in follow-up with Sleep Medicine, Pulmonology, and Endocrinology. Four months after hospitalization, his thyroid tests had normalized, and home oxygen was discontinued. The patient continues to use nocturnal AVAPS and remains on daily oral levothyroxine with continued improvement.

Discussion

Hypothyroidism is common worldwide, with a prevalence of 4.6% in the United States.¹ It is frequently found in adults older than age 65 with higher prevalence in females.² In the United States, primary hypothyroidism is often due to chronic autoimmune thyroiditis or Hashimoto's disease. It also occurs after damage or destruction of the thyroid gland after radioiodine treatment or thyroid resection.³ Congenital hypothyroidism is rare with prevalence of one in 2,000-4,000 live births.⁴

Hypothyroidism is categorized as subclinical, primary, secondary, or tertiary based on TSH and free T4 levels. Subclinical hypothyroidism presents with TSH > 4.0 mIU/L and normal T4.^{5,6} Primary hypothyroidism has elevated TSH and low free T4, less than 1.8 ng/dl.^{5,7} A low or normal TSH with a low free T4 indicates secondary or tertiary hypothyroidism, with malfunctioning of either the hypothalamus or pituitary gland.⁷

Hypothyroidism presents with a myriad of signs and symptoms, as thyroid hormone receptors regulate numerous physiological processes. The severity of these signs and symptoms reflects the degree of thyroid dysfunction and the time to develop hypothyroidism.⁷ Common symptoms of primary hypothyroidism include weight gain, fatigue, poor concentration, diffuse muscle pain, constipation, cold intolerance, dry skin, and hair thinning or loss.^{7,8} Associated laboratory findings may include hypercapnia, hypoxia, hyponatremia, elevated CK, hyperlipidemia, normocytic anemia, and hyperprolactinemia.⁷ Patients with severe hypothyroidism may present with pleural effusion, megacolon, hemodynamic instability, or pericardial effusion.⁷ Severe decompensation from hypothyroidism can result in myxedema coma, a rare complication with annual incidence of 0.22 per million. Classic features of myxedema coma are myxedema hypothermia and mental status changes of lethargy, cognitive dysfunction, or psychosis.^{8,9} Hypoventilation, hyponatremia, and bradycardia may also be associated.^{8,9}

Although primary hypothyroidism may be associated with respiratory symptoms (driven by pulmonary hypertension, pulmonary edema, upper airway myxedema, and pleural effusions) and respiratory failure, our patient was unusual presenting with severe hypoxia requiring HFNC. This patient's respiratory features mirrored physiologic alterations seen in myxedema coma. Respiratory failure with hypothyroidism can be caused by various mechanisms, including central respiratory depression due to impaired central ventilator responses to hypoxia and hypercapnia, hypoventilation due to myxedema myopathy of respiratory muscles, and obstructive sleep apnea.^{10,11} Similar cases have described patients with hypothyroidism and associated hypoxia but not to the degree requiring HFNC. One case report of a 79-year-old male with severe hypothyroidism developed respiratory arrest due to obstructive sleep apnea. This patient required continuous positive airway pressure and stabilization with BiPAP.¹²

Hypothyroidism should be treated with lifelong levothyroxine to normalize TSH and relieve clinical symptoms. Levothyroxine should be taken once per day, 30 to 60 minutes prior to eating, and four hours before or after drugs that may impede absorption such as bile acid sequestrants, calcium carbonate, ferrous sulfate, ion exchange resins, orlistat, or drugs that increase intragastric pH via hypochlorhydria.⁵ TSH should be monitored every six to eight weeks until consistently within normal range, followed by surveillance every six to twelve months.⁵ Monitored patients with abnormalities in TSH levels should be assessed for levothyroxine adherence and drug-drug interactions.⁵ Levothyroxine dosage should be adjusted every six to eight weeks until TSH normalizes. Dose may be increased

or decreased by 12.5-25 mcg.⁵ Referral to Endocrinology should be considered if there is no improvement in TSH levels after two to three cycles of adjustment.⁵

Patients with respiratory symptoms when initiating levothyroxine therapy, hypercapnia and hypoxia normalize after two to five months. Diaphragmatic muscle strength normalized within three months.¹⁰ Improvement of clinical symptoms from hypothyroidism may be gradual.

Conclusion

Hypothyroidism is a common endocrine derangement that presents with an array of clinical signs and symptoms. Respiratory symptoms can result from airway myxedema, pulmonary hypertension, pulmonary edema, and pleural effusions. The causes of respiratory failure in hypothyroidism are multifactorial. They include central respiratory depression from impaired central ventilator responses to hypoxia and hypercapnia, hypoventilation due to myxedema myopathy of respiratory muscles, or concurrent obstructive sleep apnea. It is important to note that severe respiratory symptoms of hypothyroidism are not exclusive to patients with myxedema coma. Management of severe respiratory symptoms may require non-invasive respiratory support in conjunction with intravenous levothyroxine treatment. Recovery in patients with hypothyroidism and respiratory symptoms may be prolonged. Close monitoring for relapse is needed after initial treatment.

Figures

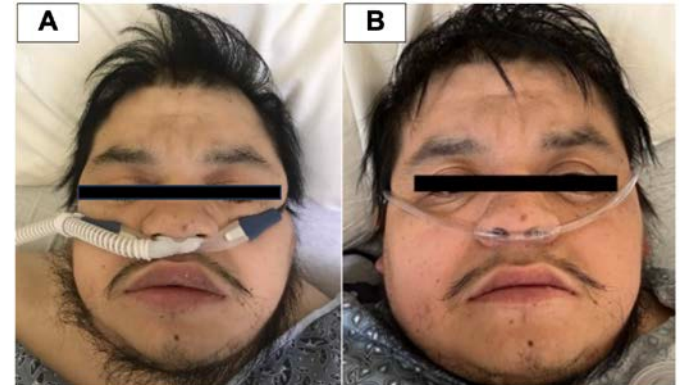

Figure 1: Patient demonstrates coarse facies, periorbital edema, facial edema, and hair thinning on hospital day 5 when HFNC was initiated (A) versus patient's appearance on hospital day 11 (B).

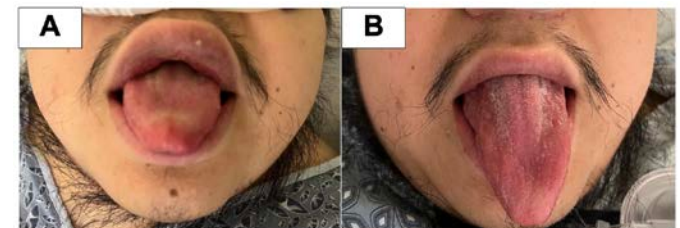

Figure 2: Patient demonstrating macroglossia on hospital day 5 (A) compared to notable improvement on hospital day 11 (B).

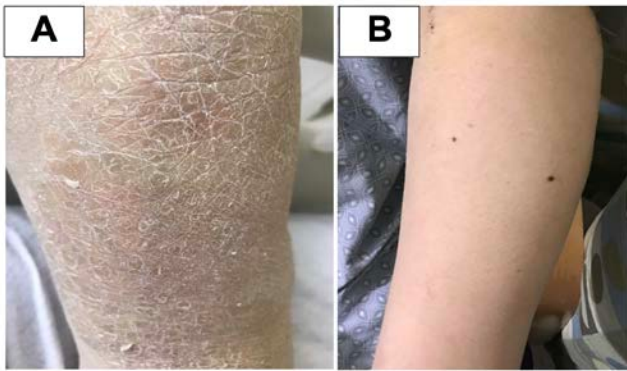

Figure 3: Patient's skin findings on day of admission (A) in comparison to time of discharge with notable improvement in dryness of skin (B).

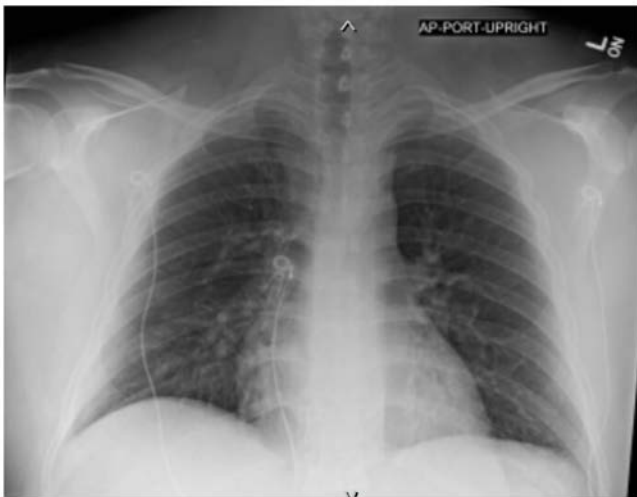


Figure 4: AP upright chest x-ray from patient's admission (hospital day 1) with unremarkable findings.

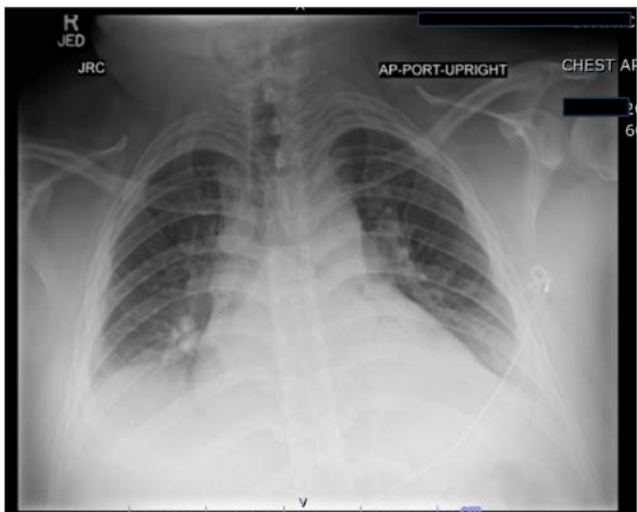


Figure 5: AP upright chest x-ray from the day of patient's ICU admission (hospital day 5), showing basilar atelectatic changes with possible consolidation (pulmonary edema versus pneumonia) with mild haziness of the costophrenic angles suggestive of a small amount of pleural fluid.

REFERENCES

1. **Hollowell JG, Staehling NW, Flanders WD, Hannon WH, Gunter EW, Spencer CA, Braverman LE.** Serum TSH, T(4), and thyroid antibodies in the United States population (1988 to 1994): National Health and Nutrition Examination Survey (NHANES III). *J Clin Endocrinol Metab.* 2002 Feb;87(2):489-99. doi: 10.1210/jcem.87.2.8182. PMID: 11836274.
2. **Boucai L, Hollowell JG, Surks MI.** An approach for development of age-, gender-, and ethnicity-specific thyrotropin reference limits. *Thyroid.* 2011 Jan;21(1):5-11. doi: 10.1089/thy.2010.0092. Epub 2010 Nov 8. PMID: 21058882; PMCID: PMC3012447.
3. **Woeber KA.** Update on the management of hyperthyroidism and hypothyroidism. *Arch Intern Med.* 2000 Apr 24;160(8):1067-71. doi: 10.1001/archinte.160.8.1067. PMID: 10789598.
4. **Jones DE, Hart K, Shapira SK, Murray M, Atkinson-Dunn R, Rohrwasser A.** Identification of Primary Congenital Hypothyroidism Based on Two Newborn Screens - Utah, 2010-2016. *MMWR Morb Mortal Wkly Rep.* 2018 Jul 20;67(28):782-785. doi: 10.15585/mmwr.mm6728a4. PMID: 30024866; PMCID: PMC6053999.
5. **Wilson SA, Stem LA, Bruehlman RD.** Hypothyroidism: Diagnosis and Treatment. *Am Fam Physician.* 2021 May 15;103(10):605-613. PMID: 33983002.
6. **Jones DD, May KE, Geraci SA.** Subclinical thyroid disease. *Am J Med.* 2010 Jun;123(6):502-4. doi: 10.1016/j.amjmed.2009.12.023. PMID: 20569751.
7. **Gaitonde DY, Rowley KD, Sweeney LB.** Hypothyroidism: an update. *Am Fam Physician.* 2012 Aug 1;86(3):244-51. PMID: 22962987.
8. **Chaker L, Bianco AC, Jonklaas J, Peeters RP.** Hypothyroidism. *Lancet.* 2017 Sep 23;390(10101):1550-1562. doi: 10.1016/S0140-6736(17)30703-1. Epub 2017 Mar 20. PMID: 28336049; PMCID: PMC6619426.
9. **Wartofsky L.** Myxedema coma. *Endocrinol Metab Clin North Am.* 2006 Dec;35(4):687-98, vii-viii. doi: 10.1016/j.ecl.2006.09.003. PMID: 17127141.
10. **Brüssel T, Matthay MA, Chernow B.** Pulmonary manifestations of endocrine and metabolic disorders. *Clin Chest Med.* 1989 Dec;10(4):645-53. PMID: 2689069.
11. **Sorensen JR, Winther KH, Bonnema SJ, Godballe C, Hegedüs L.** Respiratory Manifestations of Hypothyroidism: A Systematic Review. *Thyroid.* 2016 Nov;26(11):1519-1527. doi: 10.1089/thy.2015.0642. PMID: 27673426.
12. **Fukusumi M, Iidaka T, Mouri A, Hamamoto Y, Kamimura M.** Respiratory failure associated with hypoventilation in a patient with severe hypothyroidism. *Respirol Case Rep.* 2014 Jun;2(2):79-80. doi: 10.1002/rrc2.55. Epub 2014 Mar 13. PMID: 25473574; PMCID: PMC4184513.