

CLINICAL VIGNETTE

Sarcoidosis Presenting as Syncope in a Middle-aged Man

Abdul Elah H. Assi, MD, Melkon Hacobian, MD and Asim M. Rafique, MD

Department of Medicine, Division of Cardiology, University of California Los Angeles

Clinical Presentation

A 41-year-old male with a cardiac history of 2:1 atrioventricular block was referred for evaluation of near syncope. For six months he felt fatigued and lightheaded with exercise. Physical examination revealed blood pressure of 132/82 mmHg, heart rate of 45 beats/minute, and oxygen saturation of 98% on room air. Cardiovascular examination revealed normal heart sounds, no murmurs, no jugular venous distension, and no edema. The remaining of his physical examination was unremarkable. There was no history of hypertension, hyperlipidemia or diabetes, coronary artery disease, connective tissue disorders, or exposure to Lyme's. He smoked during college and did not drink alcohol. He was taking dextroamphetamine/amphetamine for attention deficit hyperactivity disorder. Twelve lead EKG revealed a sinus rhythm, 2:1 AV block, prolonged PR interval, and non-specific ST-T changes. A stress treadmill, revealed poor exercise tolerance, reaching 6 minutes on a Bruce protocol, and with a peak heart rate of 53 bpm (29% of maximum predicted), an inappropriate chronotropic response to exercise. He developed a complete heart block at peak exercise with AV dissociation. Transthoracic echocardiogram showed a left ventricular ejection fraction of 45-50%, severely enlarged right ventricle with moderate systolic dysfunction (Figure 1).

The patient underwent cardiac magnetic resonance (CMR) to evaluate for infiltrative disease. It revealed moderate to severely enlarged right ventricle (RV) with global hypokinesis. Additionally, there was diffuse delayed enhancement of the RV wall and patchy delayed enhancement of the left ventricular sub-endocardium (Figure 2). These clinical and imaging findings were consistent with an infiltrative cardiomyopathy. Positron emission tomography (FDG PET) showed nodular on diffuse, moderate to intense FDG uptake, consistent with cardiac sarcoidosis (CS).

Discussion

Sarcoidosis is a rare systemic inflammatory disease of unknown etiology. It is characterized by the presence of non-caseating granulomas in multiple organ systems, including lungs, skin, eyes, nervous system, and rarely the heart.¹ Untreated sarcoidosis can lead to end-organ damage including pulmonary and cardiac fibrosis.¹ In the United States, the highest sarcoidosis incidence is between 20-49 years of age. The age-adjusted annual incidence of sarcoidosis is about 35.5 per

100,000 in African Americans and 10.9 per 100,000 in Caucasians.² Cardiac involvement in sarcoidosis occurs in 5-10% of cases.¹ Although rare, it is the leading cause of death in sarcoidosis with a mortality rate of 25%.³ Complete atrioventricular block is the most common arrhythmia (30%), followed by ventricular tachycardia (VT) and ventricular fibrillation (23%), and sudden cardiac death (67%).⁴ CMR and FDG PET are critical tools for non-invasive diagnosis of CS. CMR showing late gadolinium enhancement (LGE) is considered the study of choice for diagnosing cardiac sarcoidosis.⁵ Delayed enhancement is most commonly seen in the sub-epicardium of the basal ventricular wall, the lateral wall, and septum. However, sub-endocardial enhancement has been also reported.⁶ While LGE signifies the presence of scar tissue, CMR provides additional information about wall motion and chamber size. In contrast to CMR, FDG PET can detect active myocardial inflammation. But due to a 20% false-negative rate with PET, and the high negative predictive value of CMR, it's recommended to prioritize CMR first, then supplement and assess the presence of inflammation with PET.⁶ Due to the patchy cardiac involvement of sarcoidosis, and granulomas predominantly being located in the left ventricle and basal ventricular septum than in the right ventricle EMB has been shown to have a low diagnostic yield (less than 20%).⁷ Corticosteroids have been used for decades as the first-line treatment of CS. Retrospective studies have demonstrated the direct survival benefits of corticosteroids by the reversal of atrioventricular block, and improvement in left ventricular ejection fraction.^{8,9} Second line treatment for refractory cases includes the use of immunomodulatory agents with methotrexate or azathioprine being the first choice.¹⁰

Case Course

Given the symptomatic bradycardia, the patient was referred to electrophysiology service, and a dual-chamber implantable cardioverter-defibrillators (ICD) was recommended. The patient was also referred for left heart catheterization and coronary angiography for evaluation of coronary artery disease (CAD) in the setting of heart block and mildly depressed ejection fraction. Coronary angiography showed no obstructive CAD. The patient had ICD implanted and was discharged on prednisone to follow up with Cardiology. He continued to have limited exercise capacity, and azathioprine was added to his

treatment regimen. Repeat PET scan showed no signs of active inflammation. However, the patient developed multiple episodes of VT that required ICD shock, despite antiarrhythmic medical therapy. He underwent endo/epicardial right ventricular ablation which led to the termination of his VT. Repeat CMR 3 years later revealed Right ventricular enlargement with reduced systolic function and diffuse subendocardial delayed enhancement that increased compared to prior CMR. Despite being on optimal medical therapy, the patient continues to experience progressive fatigue and limitation in exercise capacity

Learning Points

- Although rare, cardiac involvement can be the first presentation in sarcoidosis.
- Early suspicion and diagnosis of cardiac sarcoidosis are crucial for initiation of appropriate treatment as presentation and symptoms can be vague.
- Evaluation with cardiac magnetic resonance is the gold standard.
- Arrhythmia is the most feared complication of cardiac sarcoidosis. Therefore, early rhythm evaluation and referral to electrophysiology services are crucial in preventing cardiac arrest.
- Despite early and optimal intervention, cardiac sarcoidosis is a progressively debilitating disease. Patients continue to suffer from a progressive decrease in functional capacity.

Figures

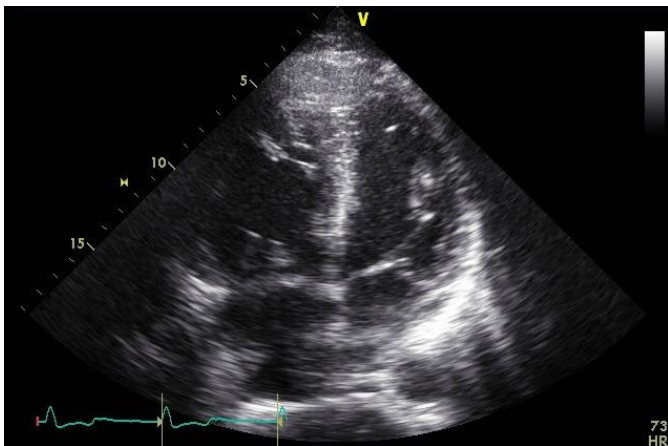


Figure 1. Transthoracic echocardiogram image with 4-chamber view showing the enlarged right ventricle.

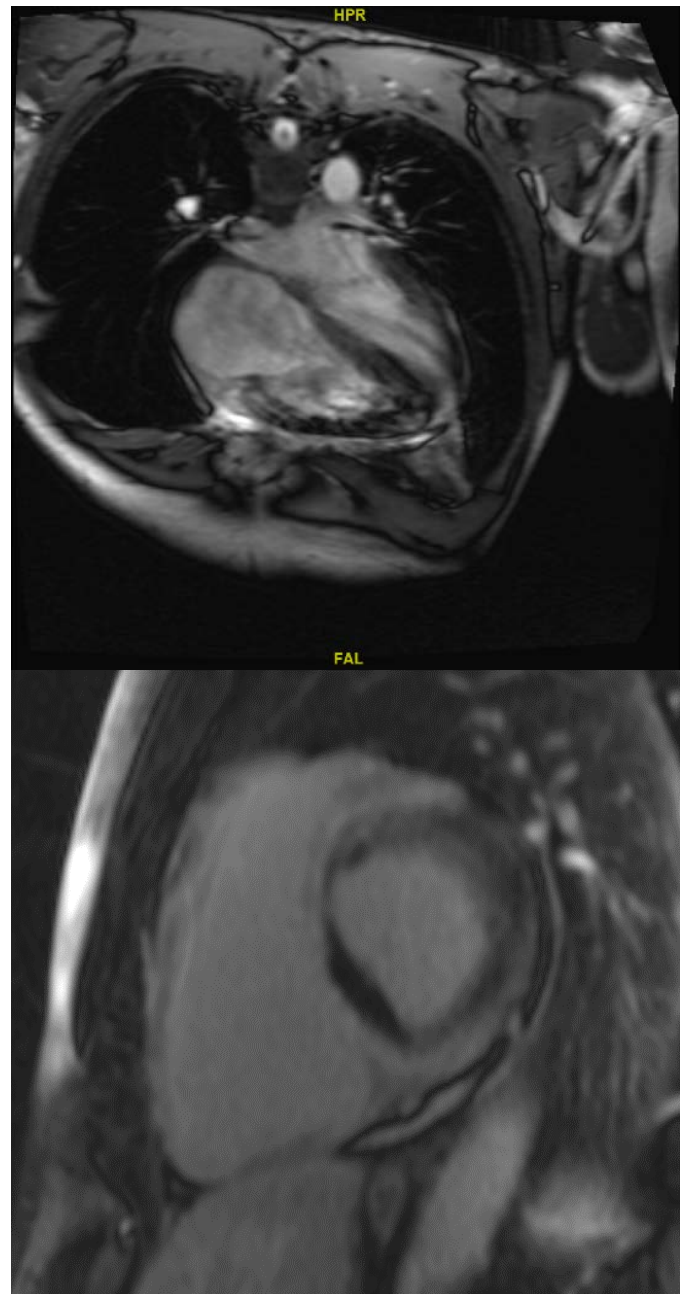


Figure 2. Cardiac magnetic resonance showing the enlarged right ventricle and diffuse delayed enhancement

REFERENCES

1. **Iannuzzi MC, Rybicki BA, Teirstein AS.** Sarcoidosis. *N Engl J Med.* 2007 Nov 22;357(21):2153-65. doi: 10.1056/NEJMra071714. PMID: 18032765.
2. **Rybicki BA, Major M, Popovich J Jr, Maliarik MJ, Iannuzzi MC.** Racial differences in sarcoidosis incidence: a 5-year study in a health maintenance organization. *Am J Epidemiol.* 1997 Feb 1;145(3):234-41. doi: 10.1093/oxfordjournals.aje.a009096. PMID: 9012596.
3. **Rao DA, Dellaripa PF.** Extrapulmonary manifestations of sarcoidosis. *Rheum Dis Clin North Am.* 2013 May;39(2):

277-97. doi: 10.1016/j.rdc.2013.02.007. Epub 2013 Mar 13. PMID: 23597964; PMCID: PMC3756667.

4. **Nery PB, Leung E, Birnie DH.** Arrhythmias in cardiac sarcoidosis: diagnosis and treatment. *Curr Opin Cardiol.* 2012 Mar;27(2):181-9. doi: 10.1097/HCO.0b013e32834e4c7c. PMID: 22186166.
5. **Patel MR, Cawley PJ, Heitner JF, Klem I, Parker MA, Jaroudi WA, Meine TJ, White JB, Elliott MD, Kim HW, Judd RM, Kim RJ.** Detection of myocardial damage in patients with sarcoidosis. *Circulation.* 2009 Nov 17;120(20):1969-77. doi: 10.1161/CIRCULATIONAHA.109.851352. Epub 2009 Nov 2. PMID: 19884472; PMCID: PMC2778859.
6. Writing group; Document reading group; EACVI Reviewers: This document was reviewed by members of the EACVI Scientific Documents Committee for 2014–2016 and 2016–2018. A joint procedural position statement on imaging in cardiac sarcoidosis: from the Cardiovascular and Inflammation & Infection Committees of the European Association of Nuclear Medicine, the European Association of Cardiovascular Imaging, and the American Society of Nuclear Cardiology. *Eur Heart J Cardiovasc Imaging.* 2017 Oct 1;18(10):1073-1089. doi: 10.1093/ehjci/jex146. PMID: 28984894.
7. **Uemura A, Morimoto S, Hiramitsu S, Kato Y, Ito T, Hishida H.** Histologic diagnostic rate of cardiac sarcoidosis: evaluation of endomyocardial biopsies. *Am Heart J.* 1999 Aug;138(2 Pt 1):299-302. doi: 10.1016/s0002-8703(99)70115-8. PMID: 10426842.
8. **Kusano KF.** Effect of corticosteroid on arrhythmic events in patients with cardiac sarcoidosis. *J Cardiol.* 2013 Nov;62(5):326-7. doi: 10.1016/j.jjcc.2013.09.004. Epub 2013 Oct 27. PMID: 24169440.
9. **Wand AL, Okada DR, Griffin JM, Kasper EK, Chen E, Gilotra NA.** Effect of corticosteroid dose and duration on left ventricular ejection fraction in cardiac sarcoidosis. *Journal of Cardiac Failure.* 2019 Aug;25(8):S69.
10. **Vorselaars ADM, Wuyts WA, Vorselaars VMM, Zanen P, Deneer VHM, Veltkamp M, Thomeer M, van Moorsel CHM, Grutters JC.** Methotrexate vs azathioprine in second-line therapy of sarcoidosis. *Chest.* 2013 Sep;144(3):805-812. doi: 10.1378/chest.12-1728. PMID: 23538719.