

## CLINICAL VIGNETTE

# Foreign Body Aspiration: A Dental Procedure Gone Awry

Rauz Eshraghi, MD and Maryum Merchant, MD

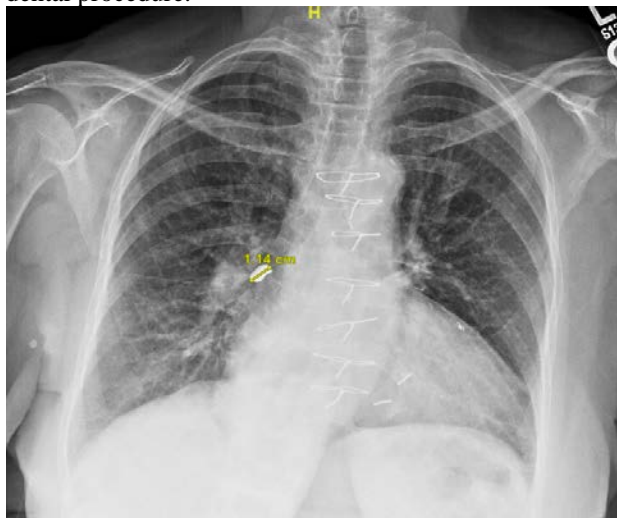
### Case Presentation

An 89-year-old woman with diabetes mellitus and coronary artery disease presented to her primary care physician with concern for aspiration of a foreign body. She was referred by her dentist after a procedure to replace a dental crown several hours earlier. During the procedure, the patient had sensed the crown in her throat and immediately began coughing. Upon evaluation in the clinic, the patient denied shortness of breath, wheezing, drooling, hemoptysis, fever or pain in the neck or chest. She still had a mild cough. She had eaten after the procedure without difficulty. On exam she was in no distress, was afebrile, with blood pressure of 161/50 mmHg, heart rate of 62 beats per minute, respiratory rate of 18 and oxygen saturation was 94% on room air. The oropharynx was clear. Her trachea was midline. She was speaking in full sentences with no respiratory distress or accessory muscle use. Auscultation of the chest was normal bilaterally. There was no stridor or wheezing. Her abdomen was soft without tenderness.

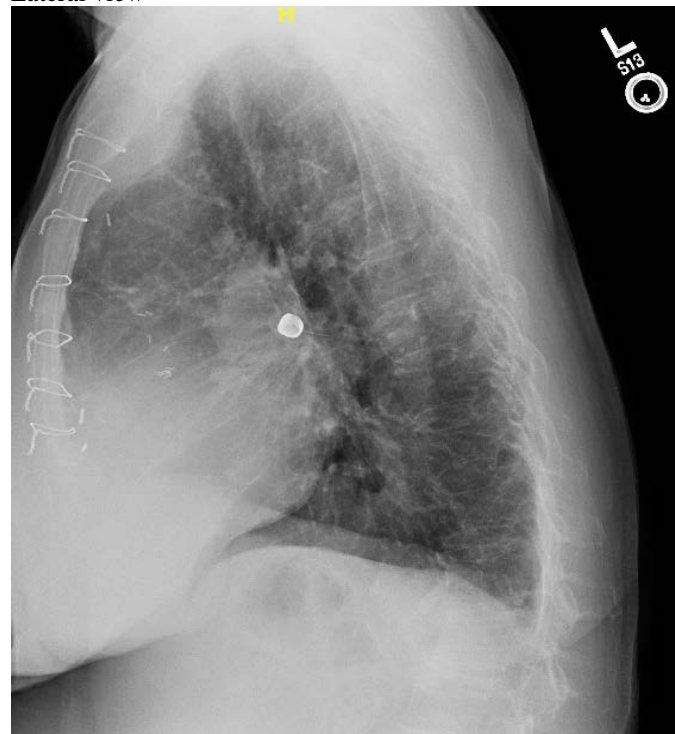### Imaging

The radiograph of the cervical spine, chest and abdomen revealed an eleven millimeter opacity projecting over the right hilum likely within the bronchus intermedius. There were minimal patchy right basilar opacities, likely atelectasis. There was no evidence of air trapping on the single inspiration radiograph.

Chest radiograph demonstrating a foreign body, 5 hours post dental procedure.



Lateral view

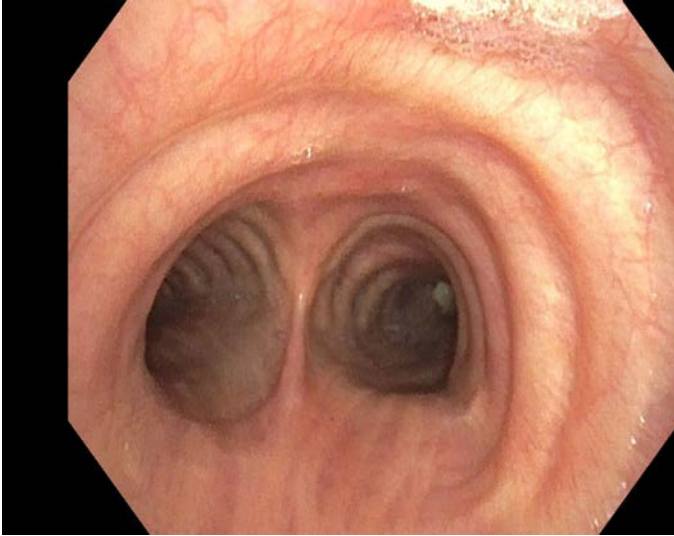


The patient was referred to interventional pulmonology and underwent urgent flexible bronchoscopy to remove the foreign body on the same day.

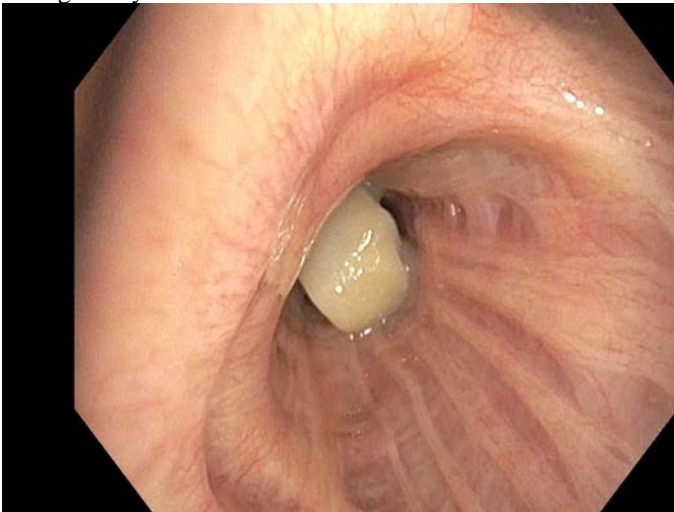
Bronchoscopy revealed normal vocal cords and trachea. Examination of the right bronchial tree revealed the dental crown in the bronchus intermedius causing total occlusion of the airway. There was also bronchomalacia of the right and left main stems with complete collapse on exhalation. Retrieval of foreign body was initially attempted with a rat tooth forceps. This was unsuccessful, as the forceps were unable to tightly grasp the object. A grasping forceps was then utilized without success. Next a Fogarty 7 balloon was inserted distally to the object and inflated. The balloon was retracted in an attempt to retrieve the object. The object eventually was pulled into the pharyngeal space. Direct laryngoscopy was then performed and the object was successfully removed with a Magill forceps. A 1.0 x 0.7 x 0.6 cm dental crown was recovered. There were no immediate complications. The patient remained overnight in

the hospital for observation and was discharged home the next day in excellent condition.

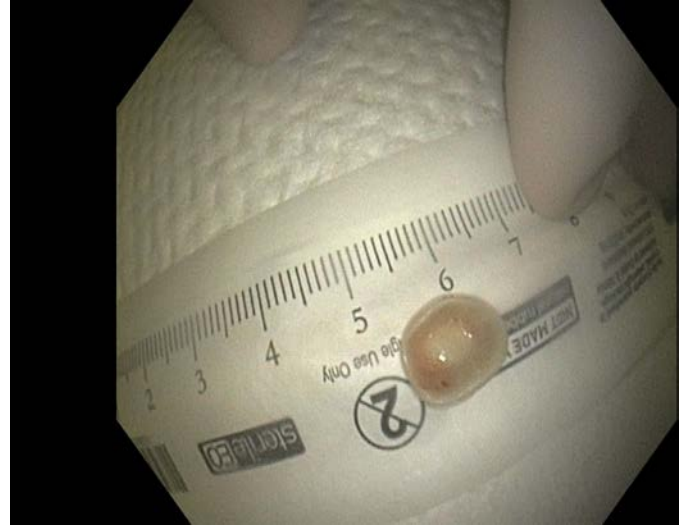Carina



Foreign body in bronchus intermedius



Foreign body (dental crown) after Removal



### *Discussion*

Aspiration of a foreign body is a relatively rare complication of dental procedures. One large retrospective evaluation of insurance company records consisting of 24,651 French dental practitioners over 11 years revealed only 44 documented aspiration events.<sup>1</sup>

### *Risk Factors and Preventative Measures*

Known risk factors for aspiration include extremes of age (less than three years old and the elderly), concurrent use of sedation, or in those with delayed swallowing reflex due to sequelae of cerebrovascular accident or other primary neurologic condition, such as amyotrophic lateral sclerosis, Parkinson's disease, or dementia causing functional impairment.<sup>2,3</sup> In non-dental settings, aspiration additionally can be seen after endotracheal intubation, as a complication of seizure activity, alcohol intoxication, or the in setting of trauma.<sup>4,5</sup>

In the dental setting, utilization of a rubber dam can help prevent aspiration or ingestion of dental tools and prosthesis, though implementation of this is not consistent.<sup>3</sup> If aspiration is suspected during a dental procedure, the patient should be advised to cough vigorously in an attempt to eject the foreign body.<sup>5</sup>

### *Signs and Symptoms*

A retrospective literature review published in 2016 found the most prevalent symptoms of foreign body aspiration were cough (66.1%), choking (27%), shortness of breath (26.6%), fever (22.2%), and hemoptysis (17.2%).<sup>6</sup> While obstruction in the upper trachea or larynx can cause acute life-threatening respiratory distress, symptoms of laryngotracheal obstruction are more typically characterized by dyspnea, cough, and stridor.<sup>3</sup> Bronchial aspiration is associated with cough, dyspnea, and wheezing.<sup>3</sup> Of note, elderly patients can present with few or no symptoms.<sup>5</sup>

Because the right main bronchus is more vertical than the left - the right bronchus is the most common site of aspiration with one review finding 71.5% of aspirated foreign bodies presenting in the right bronchial tree and 27% specifically in the intermedius bronchus.<sup>3,5,6</sup>

### **Management**

Localization is primarily achieved via chest radiography with the identification of a foreign body in 26% of cases.<sup>6</sup> Because chest radiography can be normal, bronchoscopy may still be performed if there is high clinical concern.<sup>5</sup> Bronchoscopy is a highly effective method for foreign body retrieval. While rigid bronchoscopy can provide better visualization and allow the use of additional instruments and airway suction, it requires general anesthesia.<sup>3</sup> On the other hand, flexible fiberoptic bronchoscopy can be performed under local sedation with excellent outcomes, with one review reporting 79.1% success rate.<sup>3,6</sup>

### **Complications**

If not removed, long-term complications due to foreign body aspiration can include post obstructive pneumonia, bronchial stenosis, bronchiectasis, pneumothorax, empyema or broncho-pleural fistula.<sup>2,5,6</sup> In addition, delayed detection can make foreign body removal more difficult due to granulation tissue proliferation.<sup>5</sup>

### **Conclusion**

In summary, foreign body aspiration during dental procedures is a relatively rare complication. To prevent long-term pulmonary complications, patients need to be evaluated and treated on an urgent basis. Bronchoscopy is a highly effective method of aspirated foreign body retrieval and has excellent post-procedure recovery.

### **REFERENCES**

1. **Susini G, Pommel L, Camps J.** Accidental ingestion and aspiration of root canal instruments and other dental foreign bodies in a French population. *Int Endod J.* 2007 Aug;40(8):585-9. doi: 10.1111/j.1365-2591.2007.01249.x. Epub 2007 May 26. PMID: 17532776.
2. **Limper AH, Prakash UB.** Tracheobronchial foreign bodies in adults. *Ann Intern Med.* 1990 Apr 15;112(8):604-9. doi: 10.7326/0003-4819-112-8-604. PMID: 2327678.
3. **Yadav RK, Yadav HK, Chandra A, Yadav S, Verma P, Shakya VK.** Accidental aspiration/ingestion of foreign bodies in dentistry: A clinical and legal perspective. *Natl J Maxillofac Surg.* 2015 Jul-Dec;6(2):144-51. doi: 10.4103/0975-5950.183855. PMID: 27390487; PMCID: PMC4922223.
4. **Ostrinsky Y, Cohen Z.** Images in clinical medicine. Tooth aspiration. *N Engl J Med.* 2006 Jun 15;354(24):e25. doi: 10.1056/NEJMicm050561. PMID: 16775231.
5. **Mark NM, Lessing JN, Çoruh B.** Crowning achievement: a case of dental aspiration. *Radiol Case Rep.* 2015 Oct

9;10(4):36-8. doi: 10.1016/j.radcr.2015.09.001. PMID: 26649115; PMCID: PMC4661492.

6. **Blanco Ramos M, Botana-Rial M, García-Fontán E, Fernández-Villar A, Gallas Torreira M.** Update in the extraction of airway foreign bodies in adults. *J Thorac Dis.* 2016 Nov;8(11):3452-3456. doi: 10.21037/jtd.2016.11.32. PMID: 28066626; PMCID: PMC5179474.