

## CLINICAL VIGNETTE

# A Case of Recurrent Spontaneous Pneumothoraxes

Sharon De Cruz, MD

### Case Presentation

A 35-year-old previously healthy male presented to the emergency department. He was in his usual health one day prior when he developed new onset acute shortness of breath and left sided chest pain after playing the flute. He reported rest resulted in some improvement in his symptoms but he continued to be significantly dyspneic with exertion. He denied fever, chills, night sweats, nausea, vomiting, radiating chest pain, or abdominal pain. He was a nonsmoker and denied a history of asthma. Family history was unremarkable. The patient's past medical history was remarkable for spontaneous right sided pneumothorax that occurred when he was 29 years old, which was treated with talc pleurodesis. Vital signs were significant for oxygen saturation of 94%. Physical exam revealed decreased breath sounds over the left upper lobe and small, white, dome-shaped papules over the upper back, face, and posterior neck. A chest radiograph revealed a moderate sized left pneumothorax. Computed tomography (CT) of the chest confirmed left pneumothorax and showed multiple bilateral basal predominant lung cysts. Given the patient's history, physical exam, and imaging findings, DNA sequencing was performed to evaluate for mutations in folliculin. This returned positive and he underwent left upper lobe wedge resection and talc pleurodesis with resolution of pneumothorax and symptoms. Screening abdominal CT was negative for renal tumors.

### Discussion

Brit-Hogg-Dube syndrome (BHDS) is a rare autosomal dominant monogenic disorder involving the skin, lungs, and kidneys. It is caused by mutations in the folliculin (FLCN) tumor suppressor gene that codes for the protein folliculin. The true incidence of BHD is unknown. The BHDS foundation has knowledge of 616 affected families worldwide.<sup>1</sup> Although the penetrance of FLCN mutations is high in the families affected, clinical manifestations vary broadly. These manifestations are characterized by benign skin hamartomas, pulmonary cysts, spontaneous pneumothorax, and renal tumors. In a 2008 review by Toro and colleagues that included 89 patients from 51 families, cutaneous lesions were found in 90 percent of patients, pulmonary cysts in 94 percent, history of pneumothorax in 38 percent, and renal tumors in 30 percent.<sup>2</sup>

### Pathogenesis

In 1977, Arthur R Britt, Georgina R Hogg, and James Dube first described BHDS in a family of 70 members, with 15 members

who developed fibrofolliculomas, trichodiscomas, and acrochordons after the age of 25.<sup>3</sup> These skin changes were noted to be inherited in an autosomal dominant way.<sup>4</sup> The BHDS gene locus was located in 2001 by Schmidt et al. and Khoo et al.<sup>5,6</sup> to be on the short arm of chromosome 17. In 2002 Nickerson et al.<sup>7</sup> linked BHDS to the FLCN gene on chromosome 17 which codes for the protein folliculin. FLCN was subsequently reported to be a tumor suppressor gene in 2005 when mutations were noted to result in premature termination and loss of function of folliculin.<sup>8,9</sup> Since then, other mutations have been described.<sup>10</sup>

### Diagnostic Criteria

The diagnosis of BHDS is made based upon the presence of one or more of the following criteria<sup>11</sup>:

- Identification of *FLCN* germline mutation, or
- Two or more fibrofolliculomas or trichodiscomas, with at least one histologically confirmed fibrofolliculoma, or
- Multiple bilateral basal predominant lung cysts, with or without a history of spontaneous pneumothorax, or
- Multiple bilateral chromophobe renal tumors or hybrid oncocyctic tumors especially in patients with family history of renal tumors at <50years, or
- A combination of cutaneous, pulmonary, or renal manifestations above in the patient or family member

Although genetic testing is positive in 90 percent of cases, in some patients diagnosis relies upon clinicopathologic findings.

### Clinical Manifestations

Pulmonary manifestations: Pulmonary cysts occur in about 67-90% of BHDS patients and about 40% of patients experience single or multiple episodes of spontaneous pneumothorax.<sup>2,8,12,13</sup> This high risk of spontaneous pneumothorax represents a 50-fold increased risk compared to the general population.<sup>14</sup> However, lung function is rarely affected and patients are usually asymptomatic unless a pneumothorax is present.<sup>11</sup> Pulmonary cysts are diagnosed by computed tomography (CT), and are typically multiple, bilateral, thin-walled, irregularly-shaped, and basilar-predominant.<sup>15</sup>

Differential diagnosis includes cystic lung diseases such as Langerhans cell histiocytosis and lymphangiomyomatosis (LAM) and diseases associated with increased risk of spontaneous pneumothorax such as emphysema, Marfan's syndrome, and chronic obstructive lung disease (COPD).<sup>16-19</sup>

Management of spontaneous pneumothorax in BHDS is similar to the treatment of pneumothorax of other etiologies. Patients should be advised to avoid tobacco use and exposure to high atmospheric pressure. Pleurodesis after first spontaneous pneumothorax has been suggested by some to decrease pneumothorax recurrence rate.<sup>20</sup>

### ***Skin Manifestations***

Benign skin lesions occur in approximately 60% to 90% of patients with BHDS, and typically present in the third or fourth decade of life. They consist of fibrofolliculomas, which are most common, trichodiscomas, and acrochordons.<sup>3,13,21</sup> Fibrofolliculomas are benign yellow or white dome-shaped papules, 2-4mm in size typically located in the retroauricular area, face, neck, and upper torso.<sup>21</sup> Trichodiscomas are believed to be part of the same morphological spectrum as fibrofolliculomas.<sup>21</sup> Acrochordons are skin tags that are common in the general population and are characteristic of BHDS.

Differential diagnoses for BHDS-associated skin lesions include sebaceous hyperplasia and tumors such as fibroadenoma and basal cell carcinoma.<sup>22</sup> The diagnosis of fibrofolliculomas can be verified histologically by skin biopsies.<sup>23</sup>

No curative therapy exists for these benign skin lesions. They are generally treated for cosmetic reasons with surgical or laser treatments, with high recurrence rate.<sup>21,24,25</sup>

### ***Renal Manifestations***

Renal tumors occur in approximately 14-34% of BHDS patients.<sup>26</sup> Several histologic subtypes of renal cell carcinomas (RCC) are linked to BHDS, including benign oncocytomas (5%), chromophobe RCCs (33%), hybrid chromophobe RCC-oncocytomas (50%), clear cell RCCs (9%), and papillary RCCs. Patients may present with more than one tumor histology, and tumors are often bilateral and multiple. RCCs typically develop in middle-aged patients with mean age 50.7 years.<sup>27,28</sup> Symptoms are often nonspecific and include hematuria, flank pain, and fatigue, and may not occur until disease is advanced. All BHDS patients should therefore undergo imaging with abdominal CT or magnetic resonance imaging (MRI). Diagnosis of RCC is confirmed on biopsy.

Nephron-sparing surgery is recommended for BHDS-associated renal tumors that are 3cm or larger, and any additional intraoperatively detected lesions. Renal preservation is of paramount importance as BHDS patients are at risk of developing multiple and bilateral renal tumors requiring additional surgery and potentially leading to renal insufficiency

and dialysis.<sup>29</sup> In patients with small renal tumors (<4cm), radiofrequency ablation or cryoablation may be offered.<sup>30</sup>

Prognosis in patients with renal tumors depends on tumor histology, size, and presence or absence of metastatic spread. Eighty to eighty-five percent of BHDS renal cancers are slow-growing with low potential for metastasis. Clear cell histology RCCs are more aggressive and more likely to metastasize.<sup>23</sup> Abdominal imaging to detect tumors early is therefore essential.

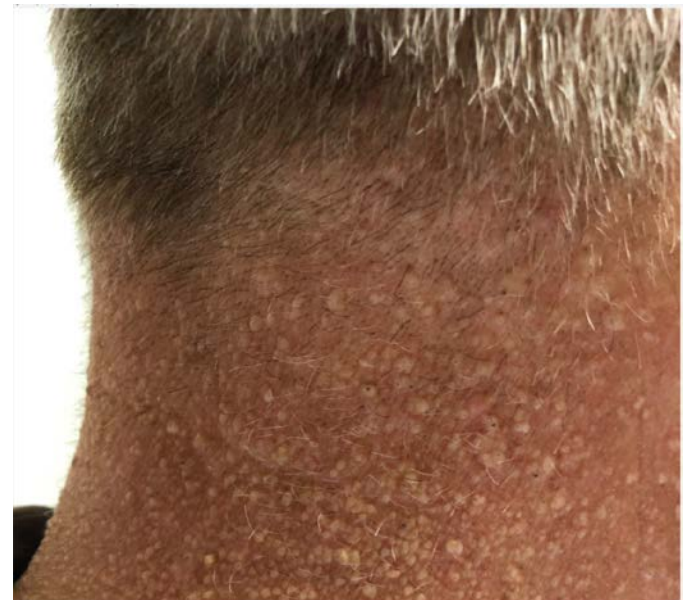### ***Prognosis***

The prognosis in BHDS is entirely dependent upon the penetrance of renal cancer and the histologic type. Deaths from renal cell carcinoma are uncommon, with the majority of fatalities occurring due to metastatic clear cell carcinoma.<sup>27,31</sup> Lifelong surveillance for renal cancer is needed in BHDS patients, however there is no clinical consensus regarding the optimal surveillance interval. The frequency and type of serial imaging should be personalized based upon the presence or absence of renal tumors and the size and growth rate of tumors that are present.<sup>29</sup>

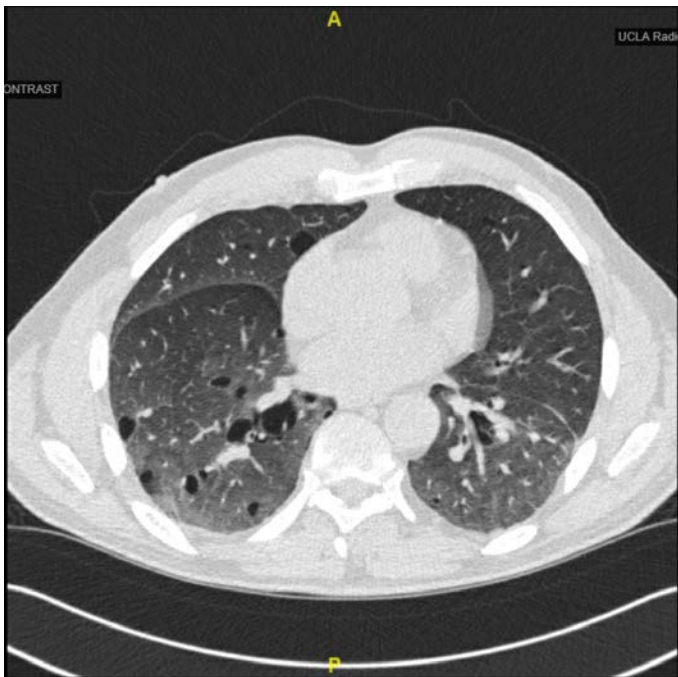
### ***Genetic Screening***

Genetic testing should be offered to all at-risk relatives starting at age 20 to 21 years once a folliculin mutation has been demonstrated, and carriers of the mutation should be offered imaging surveillance for renal cancer.<sup>29,32</sup>

### ***Figures***



**Figure 1:** Small white dome shaped papules over posterior neck consistent with fibrofolliculomas



**Figure 2:** Computed tomography of lungs showing multiple, bilateral, thin walled, irregular shaped, and basilar predominant lung cysts

## REFERENCES

1. **BHDfoundation.** Published BHD Families by the BHD foundation. Located at: <https://www.bhdsyndrome.org/for-researchers/what-is-bhd/introduction/published-bhd-families/>; Cited 2016 Dec 19.
2. **Toro JR, Wei MH, Glenn GM, Weinreich M, Toure O, Vocke C, Turner M, Choyke P, Merino MJ, Pinto PA, Steinberg SM, Schmidt LS, Linehan WM.** BHD mutations, clinical and molecular genetic investigations of Birt-Hogg-Dubé syndrome: a new series of 50 families and a review of published reports. *J Med Genet.* 2008 Jun;45(6):321-31. doi: 10.1136/jmg.2007.054304. Epub 2008 Jan 30. PMID: 18234728; PMCID: PMC2564862.
3. **Birt AR, Hogg GR, Dubé WJ.** Hereditary multiple fibrofolliculomas with trichodiscomas and acrochordons. *Arch Dermatol.* 1977 Dec;113(12):1674-7. PMID: 596896.
4. **Toro JR, Glenn G, Duray P, Darling T, Weirich G, Zbar B, Linehan M, Turner ML.** Birt-Hogg-Dubé syndrome: a novel marker of kidney neoplasia. *Arch Dermatol.* 1999 Oct;135(10):1195-202. doi: 10.1001/archderm.135.10.1195. PMID: 10522666.
5. **Schmidt LS, Warren MB, Nickerson ML, Weirich G, Matrosova V, Toro JR, Turner ML, Duray P, Merino M, Hewitt S, Pavlovich CP, Glenn G, Greenberg CR, Linehan WM, Zbar B.** Birt-Hogg-Dubé syndrome, a genodermatosis associated with spontaneous pneumothorax and kidney neoplasia, maps to chromosome 17p11.2. *Am J Hum Genet.* 2001 Oct;69(4):876-82. doi: 10.1086/323744. Epub 2001 Aug 30. PMID: 11533913; PMCID: PMC1226073.
6. **Khoo SK, Bradley M, Wong FK, Hedblad MA, Nordenskjöld M, Teh BT.** Birt-Hogg-Dubé syndrome: mapping of a novel hereditary neoplasia gene to chromosome 17p12-q11.2. *Oncogene.* 2001 Aug 23;20(37):5239-42. doi: 10.1038/sj.onc.1204703. PMID: 11526515.
7. **Nickerson ML, Warren MB, Toro JR, Matrosova V, Glenn G, Turner ML, Duray P, Merino M, Choyke P, Pavlovich CP, Sharma N, Walther M, Munroe D, Hill R, Maher E, Greenberg C, Lerman MI, Linehan WM, Zbar B, Schmidt LS.** Mutations in a novel gene lead to kidney tumors, lung wall defects, and benign tumors of the hair follicle in patients with the Birt-Hogg-Dubé syndrome. *Cancer Cell.* 2002 Aug;2(2):157-64. doi: 10.1016/s1535-6108(02)00104-6. PMID: 12204536.
8. **Schmidt LS, Nickerson ML, Warren MB, Glenn GM, Toro JR, Merino MJ, Turner ML, Choyke PL, Sharma N, Peterson J, Morrison P, Maher ER, Walther MM, Zbar B, Linehan WM.** Germline BHD-mutation spectrum and phenotype analysis of a large cohort of families with Birt-Hogg-Dubé syndrome. *Am J Hum Genet.* 2005 Jun;76(6):1023-33. doi: 10.1086/430842. Epub 2005 Apr 25. PMID: 15852235; PMCID: PMC1196440.
9. **Hasumi Y, Baba M, Ajima R, Hasumi H, Valera VA, Klein ME, Haines DC, Merino MJ, Hong SB, Yamaguchi TP, Schmidt LS, Linehan WM.** Homozygous loss of BHD causes early embryonic lethality and kidney tumor development with activation of mTORC1 and mTORC2. Version 2. *Proc Natl Acad Sci U S A.* 2009 Nov 3;106(44):18722-7. doi: 10.1073/pnas.0908853106. Epub 2009 Oct 22. PMID: 19850877; PMCID: PMC2765925.
10. **Rehman HU.** Birt-Hogg-Dubé syndrome: report of a new mutation. *Can Respir J.* 2012 May-Jun;19(3):193-5. doi: 10.1155/2012/734985. PMID: 22679611; PMCID: PMC3418093.
11. **Schmidt LS, Linehan WM.** Molecular genetics and clinical features of Birt-Hogg-Dubé syndrome. *Nat Rev Urol.* 2015 Oct;12(10):558-69. doi: 10.1038/nrur.2015.206. Epub 2015 Sep 1. PMID: 26334087; PMCID: PMC5119524.
12. **Tomassetti S, Carloni A, Chilosi M, Maffè A, Ungari S, Sverzellati N, Gurioli C, Casoni G, Romagnoli M, Gurioli C, Ravaglia C, Poletti V.** Pulmonary features of Birt-Hogg-Dubé syndrome: cystic lesions and pulmonary histiocytoma. *Respir Med.* 2011 May;105(5):768-74. doi: 10.1016/j.rmed.2011.01.002. Epub 2011 Feb 26. PMID: 21356586.
13. **Skolnik K, Tsai WH, Dornan K, Perrier R, Burrowes PW, Davidson WJ.** Birt-Hogg-Dubé syndrome: a large single family cohort. *Respir Res.* 2016 Feb 29;17:22. doi: 10.1186/s12931-016-0339-2. PMID: 26928018; PMCID: PMC4770529.
14. **Zbar B, Alvord WG, Glenn G, Turner M, Pavlovich CP, Schmidt L, Walther M, Choyke P, Weirich G, Hewitt SM, Duray P, Gabril F, Greenberg C, Merino MJ, Toro J, Linehan WM.** Risk of renal and colonic

- neoplasms and spontaneous pneumothorax in the Birt-Hogg-Dubé syndrome. *Cancer Epidemiol Biomarkers Prev*. 2002 Apr;11(4):393-400. PMID: 11927500.
15. **Gupta N, Seyama K, McCormack FX.** Pulmonary manifestations of Birt-Hogg-Dubé syndrome. *Fam Cancer*. 2013 Sep;12(3):387-96. doi: 10.1007/s10689-013-9660-9. PMID: 23715758; PMCID: PMC4409425.
  16. **Tobino K, Hirai T, Johkoh T, Kurihara M, Fujimoto K, Tomiyama N, Mishima M, Takahashi K, Seyama K.** Differentiation between Birt-Hogg-Dubé syndrome and lymphangioliomyomatosis: quantitative analysis of pulmonary cysts on computed tomography of the chest in 66 females. *Eur J Radiol*. 2012 Jun;81(6):1340-6. doi: 10.1016/j.ejrad.2011.03.039. Epub 2011 May 7. PMID: 21550193.
  17. **Fabre A, Borie R, Debray MP, Crestani B, Danel C.** Distinguishing the histological and radiological features of cystic lung disease in Birt-Hogg-Dubé syndrome from those of tobacco-related spontaneous pneumothorax. *Histopathology*. 2014 Apr;64(5):741-9. doi: 10.1111/his.12318. Epub 2013 Dec 26. PMID: 24168179.
  18. **Gupta P, Eshaghi N, Kamba TT, Ghole V, Garcia-Morales F.** Radiological findings in Birt-Hogg-Dubé syndrome: a rare differential for pulmonary cysts and renal tumors. *Clin Imaging*. 2007 Jan-Feb;31(1):40-3. doi: 10.1016/j.clinimag.2006.09.023. PMID: 17189846.
  19. **Gupta N, Vassallo R, Wikenheiser-Brokamp KA, McCormack FX.** Diffuse Cystic Lung Disease. Part I. *Am J Respir Crit Care Med*. 2015 Jun 15;191(12):1354-66. doi: 10.1164/rccm.201411-2094CI. PMID: 25906089; PMCID: PMC5442966.
  20. **Almoosa KF, Ryu JH, Mendez J, Huggins JT, Young LR, Sullivan EJ, Maurer J, McCormack FX, Sahn SA.** Management of pneumothorax in lymphangioliomyomatosis: effects on recurrence and lung transplantation complications. *Chest*. 2006 May;129(5):1274-81. doi: 10.1378/chest.129.5.1274. PMID: 16685019.
  21. **Kluger N, Giraud S, Coupier I, Avril MF, Dereure O, Guillot B, Richard S, Bessis D.** Birt-Hogg-Dubé syndrome: clinical and genetic studies of 10 French families. *Br J Dermatol*. 2010 Mar;162(3):527-37. doi: 10.1111/j.1365-2133.2009.09517.x. Epub 2009 Sep 26. PMID: 19785621.
  22. **Vincent A, Farley M, Chan E, James WD.** Birt-Hogg-Dubé syndrome: a review of the literature and the differential diagnosis of firm facial papules. *J Am Acad Dermatol*. 2003 Oct;49(4):698-705. doi: 10.1067/s0190-9622(03)01582-2. PMID: 14512919.
  23. **Jensen DK, Villumsen A, Skytte AB, Madsen MG, Sommerlund M, Bendstrup E.** Birt-Hogg-Dubé syndrome: a case report and a review of the literature. *Eur Clin Respir J*. 2017 Feb 20;4(1):1292378. doi: 10.1080/20018525.2017.1292378. PMID: 28326182; PMCID: PMC5345590.
  24. **Welsch MJ, Kronic A, Medenica MM.** Birt-Hogg-Dubé Syndrome. *Int J Dermatol*. 2005 Aug;44(8):668-73. doi: 10.1111/j.1365-4632.2004.02095.x. PMID: 16101870.
  25. **Farrant PB, Emerson R.** Letter: hyfrecreation and curettage as a treatment for fibrofolliculomas in Birt-Hogg-Dubé syndrome. *Dermatol Surg*. 2007 Oct;33(10):1287-8. doi: 10.1111/j.1524-4725.2007.33270.x. PMID: 17903168.
  26. **Gupta S, Kang HC, Ganeshan DM, Bathala TK, Kundra V.** Diagnostic approach to hereditary renal cell carcinoma. *AJR Am J Roentgenol*. 2015 May;204(5):1031-41. doi: 10.2214/AJR.14.13514. PMID: 25905938.
  27. **Benusiglio PR, Giraud S, Deveaux S, Méjean A, Correas JM, Joly D, Timsit MO, Ferlicot S, Verkarre V, Abadie C, Chauveau D, Leroux D, Avril MF, Cordier JF, Richard S; French National Cancer Institute Inherited Predisposition to Kidney Cancer Network.** Renal cell tumour characteristics in patients with the Birt-Hogg-Dubé cancer susceptibility syndrome: a retrospective, multicentre study. *Orphanet J Rare Dis*. 2014 Oct 29;9:163. doi: 10.1186/s13023-014-0163-z. PMID: 25519458; PMCID: PMC4219093.
  28. **Furuya M, Yao M, Tanaka R, Nagashima Y, Kuroda N, Hasumi H, Baba M, Matsushima J, Nomura F, Nakatani Y.** Genetic, epidemiologic and clinicopathologic studies of Japanese Asian patients with Birt-Hogg-Dubé syndrome. *Clin Genet*. 2016 Nov;90(5):403-412. doi: 10.1111/cge.12807. Epub 2016 Jun 30. PMID: 27220747.
  29. **Stamatakis L, Metwalli AR, Middleton LA, Marston Linehan W.** Diagnosis and management of BHD-associated kidney cancer. *Fam Cancer*. 2013 Sep;12(3):397-402. doi: 10.1007/s10689-013-9657-4. PMID: 23703644; PMCID: PMC4175415.
  30. **Ljungberg B, Bensalah K, Canfield S, Dabestani S, Hofmann F, Hora M, Kuczyk MA, Lam T, Marconi L, Merseburger AS, Mulders P, Powles T, Staehler M, Volpe A, Bex A.** EAU guidelines on renal cell carcinoma: 2014 update. *Eur Urol*. 2015 May;67(5):913-24. doi: 10.1016/j.eururo.2015.01.005. Epub 2015 Jan 21. PMID: 25616710.
  31. **Houweling AC, Gijzen LM, Jonker MA, van Doorn MB, Oldenburg RA, van Spaendonck-Zwarts KY, Leter EM, van Os TA, van Grieken NC, Jaspars EH, de Jong MM, Bongers EM, Johannesma PC, Postmus PE, van Moorselaar RJ, van Waesberghe JH, Starink TM, van Steensel MA, Gille JJ, Menko FH.** Renal cancer and pneumothorax risk in Birt-Hogg-Dubé syndrome; an analysis of 115 FLCN mutation carriers from 35 BHD families. *Br J Cancer*. 2011 Dec 6;105(12):1912-9. doi: 10.1038/bjc.2011.463. PMID: 22146830; PMCID: PMC3251884.
  32. **Menko FH, van Steensel MA, Giraud S, Friis-Hansen L, Richard S, Ungari S, Nordenskjöld M, Hansen TV, Solly J, Maher ER; European BHD Consortium.** Birt-Hogg-Dubé syndrome: diagnosis and management. *Lancet Oncol*. 2009 Dec;10(12):1199-206. doi: 10.1016/S1470-2045(09)70188-3. PMID: 19959076.