

## CLINICAL VIGNETTE

# Apical Hypertrophic Cardiomyopathy in Patients Presenting with SARS-CoV-2 Infection: Incidental Finding or Pathological Process?

Daniel O'Brien, MD, Adam Custer, MD, Edward Lee, MD and Reece Doughty, MD

### Abstract

Apical hypertrophic cardiomyopathy (HCM) is a rare morphologic variant of HCM involving the apex of the left ventricle (LV).<sup>1</sup> This describes two presentations of SARS-CoV-2 infection that were found to have apical HCM. While this process is often asymptomatic, it may predispose patients to worsened coronavirus outcomes.

### Case Description

We present two cases of apical hypertrophic cardiomyopathy found after presentation and admission for infection with the SARS-CoV-2 virus. The first presented after an episode of syncope with preceding diaphoresis and lightheadedness. The second presented with fevers, shortness of breath, and dizziness. Both patients tested positive for SARS-CoV-2 infection. Physical exam in both cases was notable for a regular rate and rhythm without any signs of volume overload. In both cases, EKG on presentation showed signs of left ventricular hypertrophy with large negative T-waves in the precordial leads (Figures 1, 2). One patient had evidence of myocardial injury with an elevated troponin of 2.1 ng/mL, but did not meet criteria for acute coronary syndrome. As part of their evaluation, both patients received transthoracic echocardiograms (TTE) which were consistent with a diagnosis of apical hypertrophic cardiomyopathy (Figures 1, 2). Telemetry monitoring did not reveal any significant arrhythmias. No further cardiac procedures or interventions were performed during either admission. In both cases, the severity of the SARS-CoV-2 infection was mild and supplemental oxygen was not required. Both patients had an uncomplicated hospital course and were safely discharged with close follow up.

Apical hypertrophic cardiomyopathy is an uncommon variant of hypertrophic cardiomyopathy in which the predominant area of hypertrophy is the apex of the left ventricle.<sup>1</sup> This condition is reported to have varying prevalence, representing up to 25% of HCM in Asian populations and 1-10% of HCM in other ethnicities.<sup>2</sup> The condition is often asymptomatic, but can present with angina, heart failure, myocardial infarction, arrhythmia, or syncope.<sup>1,3</sup> While there are no specific diagnostic criteria, typical features of apical HCM include large negative T waves on EKG, particularly in the precordial leads, and a "spade-like" configuration of the LV cavity at end diastole on imaging.<sup>4,5</sup> Treatment typically involves close clinical follow up and management of associated complications.<sup>1</sup> In contrast

to typical HCM, septal reduction therapy and implantable cardioverter defibrillators are often not required.<sup>1,3</sup> Apical HCM should be distinguished from the more common asymmetric septal HCM because the risk of left ventricular outflow tract obstruction is not typically present. As a result, this process carries a better long-term prognosis, with an overall survival 15 year survival of 95%.<sup>2</sup> However, the apical variant can still cause midventricular obstruction and is associated with rates of cardiac events approaching those of typical HCM.<sup>2</sup>

These two cases raise the consideration of whether apical hypertrophic cardiomyopathy contributed to the presenting symptoms, or whether they were simply incidental findings. In both cases, the presenting symptoms could have been related to the underlying SARS-CoV-2 infection, complications of apical HCM, or a combination of both. With a high-index of suspicion for cardiac complications associated with the SARS-CoV-2 infection, which can include cardiomyopathy, pericarditis, pericardial effusions, arrhythmias, and sudden cardiac death, both patients received thorough cardiac testing including TTE.<sup>6-8</sup> It is possible the increased diagnostic testing led to incidental findings. However, it is also possible that the presence of apical hypertrophic cardiomyopathy contributed to their presentation. Although LV outflow tract obstruction is uncommon in apical HCM, midventricular obstruction and cavity obliteration can lead to symptoms of syncope and arrhythmias.<sup>2</sup> SARS-CoV-2 has been shown to cause fevers, nausea, vomiting, and decreased oral intake, all of which can contribute to states of hypovolemia.<sup>9</sup> It is possible that their viral infections led to hypovolemic states that caused worsening obstruction that precipitated their symptoms. It is unknown whether apical HCM has any prognostic implications in patients presenting with SARS-CoV-2 infection or whether increased diagnostic imaging has led to more incidental diagnoses of apical HCM. As the number of coronavirus cases increases, further study of the prevalence and outcomes of patients presenting with SARS-CoV-2 infection and underlying cardiac disease such as apical HCM are warranted.

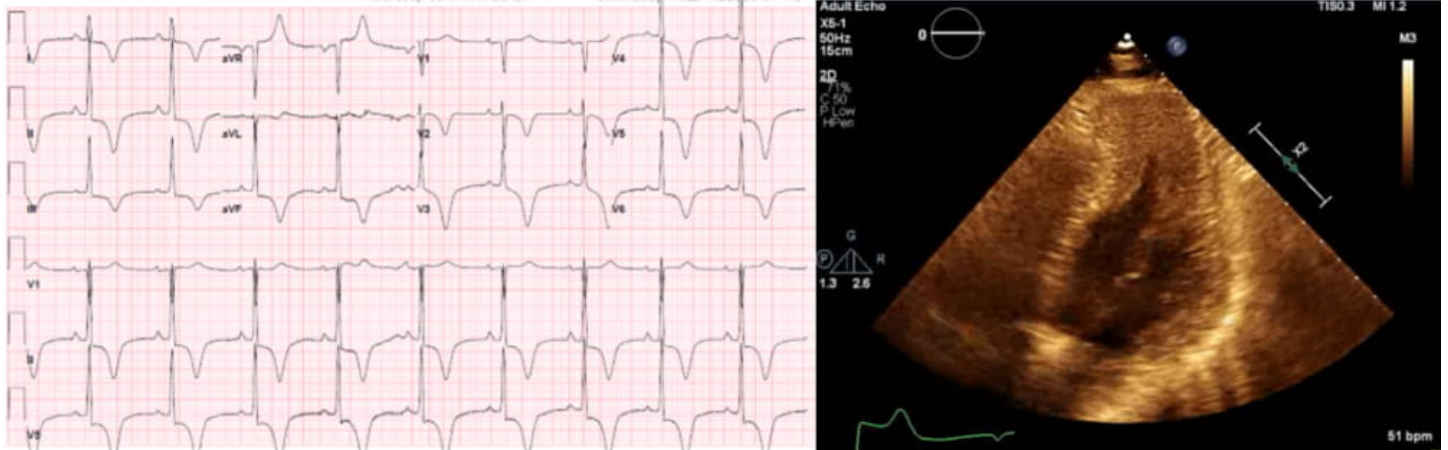
### Learning Objectives

1. Recognize the signs and symptoms associated with apical hypertrophic cardiomyopathy

2. Be aware of the cardiac complications associated with SARS-CoV-2 infection and how this can impact underlying cardiac conditions

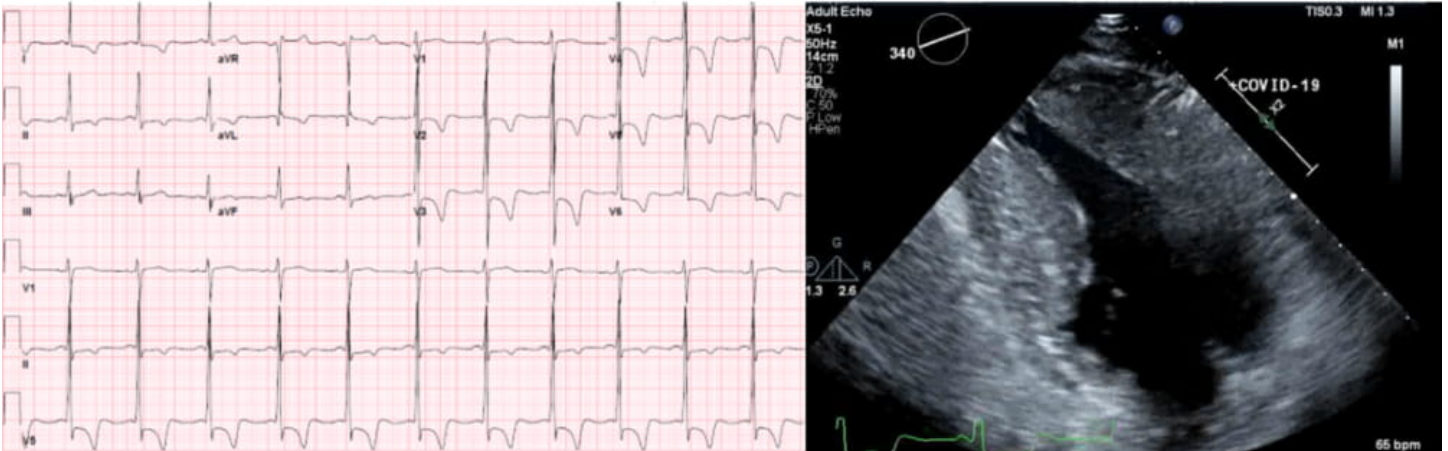
## Figures

**Figure 1:** Electrocardiogram and Transthoracic Echocardiogram for Patient 1



EKG (left) showing left ventricular hypertrophy and large T-wave inversions in leads I, II, III, aVF, and V2-V6. Transthoracic echocardiogram (right) showing apical hypertrophy with classic “spade-like” pattern.

**Figure 2:** Electrocardiogram and Transthoracic Echocardiogram for Patient 2



EKG (left) showing left ventricular hypertrophy and large T-wave inversions in leads V2-V6. Transthoracic echocardiogram (right) showing apical hypertrophy with classic “spade-like” pattern.

## REFERENCES

1. Gersh BJ, Maron BJ, Bonow RO, Dearani JA, Fifer MA, Link MS, Naidu SS, Nishimura RA, Ommen SR, Rakowski H, Seidman CE, Towbin JA, Udelson JE, Yancy CW; American College of Cardiology Foundation/American Heart Association Task Force on Practice Guidelines; American Association for Thoracic Surgery; American Society of Echocardiography; American Society of Nuclear Cardiology; Heart Failure Society of America; Heart Rhythm Society; Society for Cardiovascular Angiography and Interventions; Society of Thoracic Surgeons. 2011 ACCF/AHA guideline for the diagnosis and treatment of hypertrophic cardiomyopathy: executive summary: a report of the American College of Cardiology Foundation/American Heart Association Task Force on Practice Guidelines. *Circulation*. 2011 Dec 13;124(24):2761-96. doi: 10.1161/CIR.0b013e318223e230. Epub 2011 Nov 8. PMID: 22068435.
2. Eriksson MJ, Sonnenberg B, Woo A, Rakowski P, Parker TG, Wigle ED, Rakowski H. Long-term outcome in patients with apical hypertrophic cardiomyopathy. *J Am Coll Cardiol*. 2002 Feb 20;39(4):638-45. doi: 10.1016/s0735-1097(01)01778-8. PMID: 11849863.

3. **Hughes RK, Knott KD, Malcolmson J, Augusto JB, Mohiddin SA, Kellman P, Moon JC, Captur G.** Apical Hypertrophic Cardiomyopathy: The Variant Less Known. *J Am Heart Assoc.* 2020 Mar 3;9(5):e015294. doi: 10.1161/JAHA.119.015294. Epub 2020 Feb 28. PMID: 32106746; PMCID: PMC7335568.
4. **Yamaguchi H, Ishimura T, Nishiyama S, Nagasaki F, Nakanishi S, Takatsu F, Nishijo T, Umeda T, Machii K.** Hypertrophic nonobstructive cardiomyopathy with giant negative T waves (apical hypertrophy): ventriculographic and echocardiographic features in 30 patients. *Am J Cardiol.* 1979 Sep;44(3):401-12. doi: 10.1016/0002-9149(79)90388-6. PMID: 573056.
5. **Chen CC, Lei MH, Hsu YC, Chung SL, Sung YJ.** Apical hypertrophic cardiomyopathy: correlations between echocardiographic parameters, angiographic left ventricular morphology, and clinical outcomes. *Clin Cardiol.* 2011 Apr;34(4):233-8. doi: 10.1002/clc.20874. Epub 2011 Mar 13. PMID: 21400548; PMCID: PMC6652360.
6. **Arentz M, Yim E, Klaff L, Lokhandwala S, Riedo FX, Chong M, Lee M.** Characteristics and Outcomes of 21 Critically Ill Patients With COVID-19 in Washington State. *JAMA.* 2020 Mar 19;323(16):1612-4. doi: 10.1001/jama.2020.4326. Epub ahead of print. PMID: 32191259; PMCID: PMC7082763.
7. **Goyal P, Choi JJ, Pinheiro LC, Schenck EJ, Chen R, Jabri A, Satlin MJ, Campion TR Jr, Nahid M, Ringel JB, Hoffman KL, Alshak MN, Li HA, Wehmeyer GT, Rajan M, Reshetnyak E, Hupert N, Horn EM, Martinez FJ, Gulick RM, Safford MM.** Clinical Characteristics of Covid-19 in New York City. *N Engl J Med.* 2020 Jun 11; 382(24):2372-2374. doi: 10.1056/NEJMc2010419. Epub 2020 Apr 17. PMID: 32302078; PMCID: PMC7182018.
8. **Yang X, Yu Y, Xu J, Shu H, Xia J, Liu H, Wu Y, Zhang L, Yu Z, Fang M, Yu T, Wang Y, Pan S, Zou X, Yuan S, Shang Y.** Clinical course and outcomes of critically ill patients with SARS-CoV-2 pneumonia in Wuhan, China: a single-centered, retrospective, observational study. *Lancet Respir Med.* 2020 May;8(5):475-481. doi: 10.1016/S2213-2600(20)30079-5. Epub 2020 Feb 24. Erratum in: *Lancet Respir Med.* 2020 Apr;8(4):e26. PMID: 32105632; PMCID: PMC7102538.
9. **Cohen PA, Hall LE, John JN, Rapoport AB.** The Early Natural History of SARS- CoV-2 Infection: Clinical Observations From an Urban, Ambulatory COVID-19 Clinic. *Mayo Clin Proc.* 2020 Jun;95(6):1124-1126. doi: 10.1016/j.mayocp.2020.04.010. Epub 2020 Apr 20. PMID: 32451119; PMCID: PMC7167572.