

## CLINICAL VIGNETTE

# Delayed Reversibility of Late Bioprosthetic Valve Thrombosis

Pooja S. Desai, MD<sup>1</sup>, Ravi H. Dave, MD<sup>2</sup>, Shipra Hingorany, MD<sup>2</sup> and Ramin Tabibiazar, MD<sup>2</sup>

<sup>1</sup>Department of Medicine, UCLA Medical Center, Los Angeles, CA

<sup>2</sup>Division of Cardiology, UCLA Medical Center, Los Angeles, CA

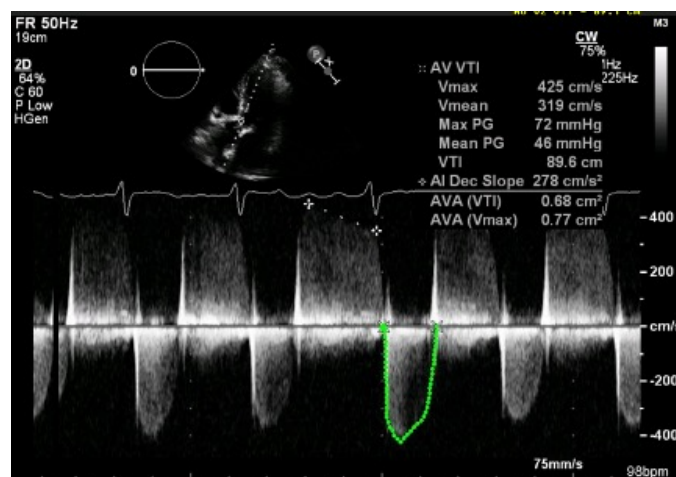
### Case Presentation

A 63-year-old male with a history of human immunodeficiency virus [HIV] and aortic stenosis status post bovine bioprosthetic valve replacement presented with New York Heart Association [NYHA] Class III symptoms and was admitted. Admission vitals were notable for tachycardia of 140 beats/minute. Physical exam revealed an irregularly irregular rhythm with tachycardia on cardiac auscultation, jugular venous pulsation of 8 cm above the sternal angle, and 1+ pitting edema of bilateral lower extremities. He had normal work of breathing, no cutaneous petechiae, and no splinter hemorrhages.

Admission laboratory studies were notable for blood urea nitrogen of 20 mg/dL, creatinine 1.55 mg/dL, brain natriuretic peptide of 380 ng/dL. Arterial blood gas was notable for pH 7.4, pCO<sub>2</sub> 27 mmHg, pO<sub>2</sub> 73 mmHg. Urinalysis had 1+ protein. Other studies including white blood cell count, troponin, erythrocyte sedimentation rate and C-reactive protein were within normal limits. Chest radiograph revealed mild pulmonary congestion. Electrocardiogram was notable for an atrial fibrillation with rapid ventricular rate [RVR].

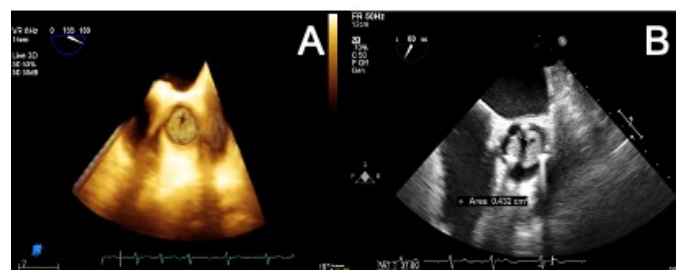
Past medical history includes a 22-year history of human immunodeficiency virus [HIV] on antiretroviral therapy, initially diagnosed when patient presented with opportunistic infections including *Mycobacterium avium* complex, *Pneumocystis jirovecii* pneumonia, cytomegalovirus retinitis, and toxoplasmosis. Four years prior, the patient presented with shortness of breath and was found to have rapid atrial fibrillation and severe aortic stenosis. At that time, cardiac catheterization revealed no coronary artery disease. He subsequently underwent a surgical aortic valve replacement [SAVR] with a Carpentier-Edwards Magna pericardial valve with simultaneous pulmonary vein ablation, after which he took warfarin for three months.

Upon admission, transthoracic echocardiogram [TTE] was notable for severe stenosis of the bioprosthetic valve with peak velocity at 4.27 m/s, peak gradient of 73.1 mmHg, mean gradient of 46.0 mmHg, and aortic valve area of 0.7 cm<sup>2</sup> (Figure 1).



**Figure 1.** TTE During Presenting Hospitalization: Apical five-chamber view via transthoracic echocardiogram reveals severely elevated pressure gradient and velocity across the valve.

Transesophageal echocardiography [TEE] revealed marked aortic valve thickening and restricted mobility of the leaflets (Figure 2).

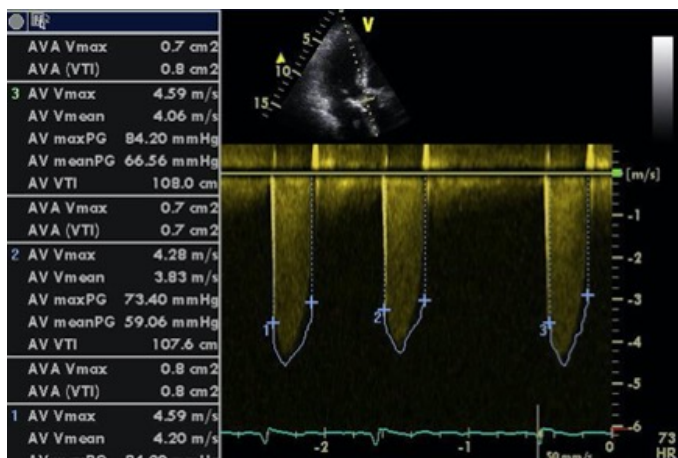


**Figure 2.** Transesophageal Echocardiography During Presenting Hospitalization: Transesophageal echocardiography reveals A) abnormal cusp motion, marked leaflet thickening, and B) severe stenosis of the bioprosthetic aortic valve.

Bacterial and fungal blood cultures were negative. Polymerase chain reaction for *Bartonella* spp and *Coxiella* spp were negative.

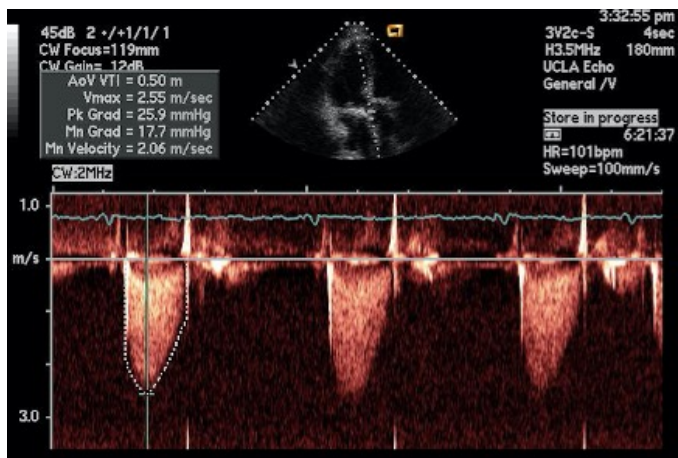
Out of concern that the echocardiographic findings suggested bioprosthetic valve thrombosis [BPVT], and for his CHA<sub>2</sub>DS<sub>2</sub>-Vasc score of 3, the patient was bridged to warfarin. The patient's RVR was controlled medically and his dyspnea improved to NYHA Class II. Urgent fibrinolysis or re-do surgery was deferred in lieu of outpatient management.

At thirty days following discharge, repeat TTE did not show improvement in pressure gradients or aortic valve area (Figure 3).

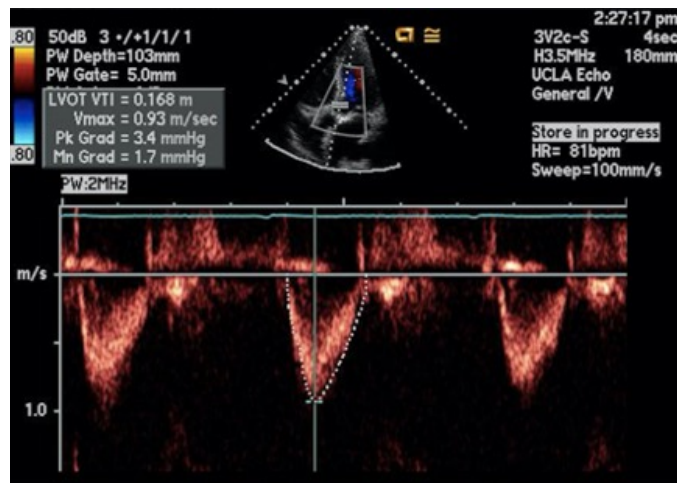


**Figure 3.** Repeat TTE at One Month of Anticoagulation: Apical five-chamber view reveals no improvement in aortic valve functioning.

The patient continued to report only mild dyspnea with exertion, and declined evaluation for re-do surgical valve repair. At six and sixteen months post-discharge, TTE demonstrated significant improvements including peak aortic velocity of 2.58 m/s and 2.25 m/s, mean pressure gradient of 18.5 mmHg and 9.9 mmHg, and aortic valve area of 1.4 cm<sup>2</sup> and 1.4 cm<sup>2</sup>, respectively (Figures 4-5). All hemodynamics are summarized in Table 1.



**Figure 4:** Repeat TTE at Six Months of Anticoagulation: Apical five-chamber view at six months reveals an aortic valve that is less stenotic with improving pressure gradients and velocity.



**Figure 5:** Repeat TTE at Sixteen Months of Anticoagulation: Apical five-chamber view reveals that the aortic valve pressure gradients and calculated valvular area are back to his baseline.

TTE relative to presenting hospitalization (months)	Aortic Valve Mean Pressure Gradient (mmHg)	Aortic Valve Peak Pressure Gradient (mmHg)	Aortic Valve Area (cm <sup>2</sup> )	Aortic Valve Peak Velocity (m/sec)
-15 (baseline)	9.5	15.7	1.5	1.98
0 (Presenting hospitalization)	46.0	73.1	0.7	4.27
+ 1	63.0	78.9	0.7	4.44
+ 6	18.5	26.6	1.4	2.58
+ 16	9.9	20.2	1.4	2.25

**Table 1:** Serial Echocardiographic Measurements of Aortic Valve Pressure Gradients, Velocity, and Area

The patient took warfarin for three years after which he self-discontinued. He repeats TTE every year without evidence of valvular abnormality. He has had no other cardiac-related hospitalizations.

### Discussion

This case describes a rare instance of very late BPVT four years after surgical replacement in an HIV+ patient. This case is particularly interesting because the thrombosis did not show improvement after one month of anticoagulation.

Bioprosthetic valves are less thrombogenic than mechanical valves, attributed to antithrombotic endothelium and more natural leaflet hemodynamics.<sup>1</sup> Bioprostheses have been increasingly utilized due to an aging recipient population in whom oral anticoagulation is not as safe.

Recently, there has been increased scrutiny on BPVT out of concern that the incidence is higher than originally understood. Retrospective analyses have estimated the incidence of BPVT between 0.03%-0.74%.<sup>2</sup> The largest related observational study found that up to 180 days post-SAVR, warfarin was associated

with decreased risk of stroke, thromboembolism, and cardiovascular death.<sup>3</sup> Incidence later than this time period has not been well-established, but one retrospective analysis did identify significant rates of occurrence 2-5 years post-operatively.<sup>4</sup> Thus, the American College of Cardiology/American Heart Association recently extended its recommendation on duration of vitamin K antagonist therapy in bioprosthetic SAVR recipients from 3 to 3-6 months.<sup>5</sup>

TTE and TEE were the cornerstone diagnostic tools in this case. Echocardiographic diagnosis of BPVT and differentiation from pannus or infectious vegetation is difficult. National guidelines suggest that thrombi can be larger with softer sonographic density than pannus.<sup>6</sup> One study identified predictors for BPVT including 50% increase in the transvalvular gradient, abnormal cusp motion, increased cusp thickening, and paroxysmal atrial fibrillation associated with subtherapeutic INR if on warfarin therapy.<sup>7</sup> Notably, cardiac computed tomography was not employed, but may have been a reasonable modality if echocardiographic images were inadequate, as discussed in national guidelines.<sup>8</sup>

Valvular degeneration was felt to be unlikely at only four-years post operation. Suspicion for endocarditis was also low given lack of fever, leukocytosis, and otherwise negative review of systems. Culture-negative endocarditis was considered, but the patient had no abnormal exposures or travel, and was a native of the United States.

It is important to consider other comorbidities in this patient. HIV alone portends a hypercoagulable state,<sup>9</sup> and is an independent predictor of valvular calcification.<sup>10</sup> Further, his proteinuria is associated with hypercoagulability via the loss of antithrombin III. Finally, if he had ongoing, unnoticed atrial fibrillation, this may have increased his risk of valvular thrombosis.

Current guidelines recommend that for patients with BPVT and NYHA III-IV symptoms, evaluation for urgent intervention should be initiated. This patient was less symptomatic and was resistant to intervention. Utilizing shared decision-making, anticoagulation was trialed with close monitoring even after there was no improvement at one month.

## REFERENCES

1. **Jaffer IH, Fredenburgh JC, Hirsh J, Weitz JI.** Medical device-induced thrombosis: what causes it and how can we prevent it? *J Thromb Haemost.* 2015 Jun;13 Suppl 1:S72-81. doi: 10.1111/jth.12961. Review. PubMed PMID: 26149053.
2. **Puvimanasinghe JP, Steyerberg EW, Takkenberg JJ, Eijkemans MJ, van Herwerden LA, Bogers AJ, Habbema JD.** Prognosis after aortic valve replacement with a bioprosthesis: predictions based on meta-analysis and microsimulation. *Circulation.* 2001 Mar 20;103(11):1535-41. PubMed PMID: 11257081.

3. **Mérie C, Køber L, Skov Olsen P, Andersson C, Gislason G, Skov Jensen J, Torp-Pedersen C.** Association of warfarin therapy duration after bioprosthetic aortic valve replacement with risk of mortality, thromboembolic complications, and bleeding. *JAMA.* 2012 Nov 28;308(20):2118-25. doi: 10.1001/jama.2012.54506. PubMed PMID: 23188028.
4. **Stortecky S, Windecker S.** Stroke: an infrequent but devastating complication in cardiovascular interventions. *Circulation.* 2012 Dec 18;126(25):2921-4. doi: 10.1161/CIRCULATIONAHA.112.149492. PubMed PMID: 23248061.
5. **Nishimura RA, Otto CM, Bonow RO, Carabello BA, Erwin JP 3rd, Fleisher LA, Jneid H, Mack MJ, McLeod CJ, O'Gara PT, Rigolin VH, Sundt TM 3rd, Thompson A.** 2017 AHA/ACC Focused Update of the 2014 AHA/ACC Guideline for the Management of Patients With Valvular Heart Disease: A Report of the American College of Cardiology/American Heart Association Task Force on Clinical Practice Guidelines. *J Am Coll Cardiol.* 2017 Jul 11;70(2):252-289. doi: 10.1016/j.jacc.2017.03.011. Epub 2017 Mar 15. PubMed PMID: 28315732.
6. **Zoghbi WA, Chambers JB, Dumesnil JG, Foster E, Gottdiener JS, Grayburn PA, Khandheria BK, Levine RA, Marx GR, Miller FA Jr, Nakatani S, Quiñones MA, Rakowski H, Rodriguez LL, Swaminathan M, Waggoner AD, Weissman NJ, Zabalgoitia M; American Society of Echocardiography's Guidelines and Standards Committee; Task Force on Prosthetic Valves; American College of Cardiology Cardiovascular Imaging Committee; Cardiac Imaging Committee of the American Heart Association; European Association of Echocardiography; European Society of Cardiology; Japanese Society of Echocardiography; Canadian Society of Echocardiography; American College of Cardiology Foundation; American Heart Association; European Association of Echocardiography; European Society of Cardiology; Japanese Society of Echocardiography; Canadian Society of Echocardiography.** Recommendations for evaluation of prosthetic valves with echocardiography and doppler ultrasound: a report From the American Society of Echocardiography's Guidelines and Standards Committee and the Task Force on Prosthetic Valves, developed in conjunction with the American College of Cardiology Cardiovascular Imaging Committee, Cardiac Imaging Committee of the American Heart Association, the European Association of Echocardiography, a registered branch of the European Society of Cardiology, the Japanese Society of Echocardiography and the Canadian Society of Echocardiography, endorsed by the American College of Cardiology Foundation, American Heart Association, European Association of Echocardiography, a registered branch of the European Society of Cardiology, the Japanese Society of Echocardiography, and Canadian Society of Echocardiography. *J Am Soc Echocardiogr.* 2009 Sep;22(9):975-1014; quiz 1082-4. doi: 10.1016/j.echo.2009.07.013. PubMed PMID: 19733789.

7. **Egbe AC, Pislaru SV, Pellikka PA, Poterucha JT, Schaff HV, Maleszewski JJ, Connolly HM.** Bioprosthetic Valve Thrombosis Versus Structural Failure: Clinical and Echocardiographic Predictors. *J Am Coll Cardiol.* 2015 Dec 1;66(21):2285-2294. doi: 10.1016/j.jacc.2015.09.022. PubMed PMID: 26610876.
8. **Doherty JU, Kort S, Mehran R, Schoenhagen P, Soman P.** ACC/AATS/AHA/ASE/ASNC/HRS/SCAI/SCCT/SCMR/ STS 2017 Appropriate Use Criteria for Multimodality Imaging in Valvular Heart Disease: A Report of the American College of Cardiology Appropriate Use Criteria Task Force, American Association for Thoracic Surgery, American Heart Association, American Society of Echocardiography, American Society of Nuclear Cardiology, Heart Rhythm Society, Society for Cardiovascular Angiography and Interventions, Society of Cardiovascular Computed Tomography, Society for Cardiovascular Magnetic Resonance, and Society of Thoracic Surgeons. *J Am Coll Cardiol.* 2017 Sep 26;70(13):1647-1672. doi: 10.1016/j.jacc.2017.07.732. Epub 2017 Sep 1. PubMed PMID: 28870679.
9. **Shen YM, Frenkel EP.** Thrombosis and a hypercoagulable state in HIV-infected patients. *Clin Appl Thromb Hemost.* 2004 Jul;10(3):277-80. Review. PubMed PMID: 15247986.
10. **Rezaeian P, Miller PE, Haberlen SA, Razipour A, Bahrami H, Castillo R, Witt MD, Kingsley L, Palella FJ Jr, Nakanishi R, Matsumoto S, Alani A, Jacobson LP, Post WS, Budoff MJ.** Extra-coronary calcification (aortic valve calcification, mitral annular calcification, aortic valve ring calcification and thoracic aortic calcification) in HIV seropositive and seronegative men: Multicenter AIDS Cohort Study. *J Cardiovasc Comput Tomogr.* 2016 May-Jun;10(3):229-236. doi: 10.1016/j.jcct.2016.02.002. Epub 2016 Feb 27. PubMed PMID: 26949197; PubMed Central PMCID: PMC4893917.