

CLINICAL VIGNETTE

Unilateral Renal Cystic Disease: A Rare Disease

Thomas Jessie Aldan, MD and Igor Kagan, MD

Abstract

Unilateral renal cystic disease is an uncommon disease that is characterized by multiple cysts with intervening normal parenchyma in one kidney or a portion of one kidney. It is a benign, nonfamilial, nonprogressive, nonencapsulated, and not associated with cysts or malformations in other organs, which distinguishes it from other kidney cystic diseases like autosomal dominant polycystic kidney disease (ADPKD). It is commonly diagnosed incidentally on imaging. No treatment is required but serial imaging is required to monitor for renal cyst progression. We present a case to elaborate on these clinical points.

Introduction

Unilateral renal cystic disease was first suggested by Levine and Huntrakoon in 1989 to describe an entity that usually manifests as a conglomeration of simple cysts, often localized to one portion of one kidney but in some cases may be diffusely present throughout the kidney.^{1,2} The entity has also been called unilateral polycystic kidney disease, localized cystic disease of kidney, and segmental polycystic kidney. The disease is characterized by replacement of renal parenchyma, either total or localized to a portion of kidney, by multiple cysts.³

We present another case of this rare disorder.

Case Report

A 66-year-old woman with past medical history of hypertension, angina, dyslipidemia, brain tumor, vitamin D deficiency, hypothyroidism, gastrointestinal reflux disease (GERD) and smoking presented for evaluation of kidney cysts.

Patient reported that earlier in the year she started having abdominal pain and underwent imaging. She was found to have numerous cysts on the left kidney and only a few cysts on the right kidney. She reported nuclear medicine imaging noted that the left kidney was only functioning at 14%.

Blood pressures at home were 130-135/75 mm Hg. She denied nonsteroidal inflammatory drug (NSAID) use and intravenous contrast exposure. She reported a headache 3-4 times per week and sometimes wakes up with a headache. She reported a history of benign brain tumor which was found 3 years prior to outpatient nephrology consultation.

Family history was significant for sister with an unprovoked brain bleed. Denied any other family history of kidney disease.

Social history was significant for a greater than 25-year smoking history. She denied herbal medicine use.

Pertinent medications included irbesartan 150 mg daily, isosorbide mononitrate 30 mg daily, metoprolol succinate 50 mg daily, levothyroxine 100 mcg daily, clonazepam 1 mg daily, and pravastatin 10 mg daily.

Surgical history was significant for appendectomy, cholecystectomy, and hysterectomy.

Physical exam showed a blood pressure 164/79 and pulse 69. She was otherwise, euvolemic and unremarkable.

Her basic metabolic panel was within normal limits with a BUN 12 and creatinine of 0.80. Her TSH, complete blood cell count, and vitamin D levels were within normal limits as well. Computed tomography (CT) of abdomen/pelvis was obtained (Figures 1-3).

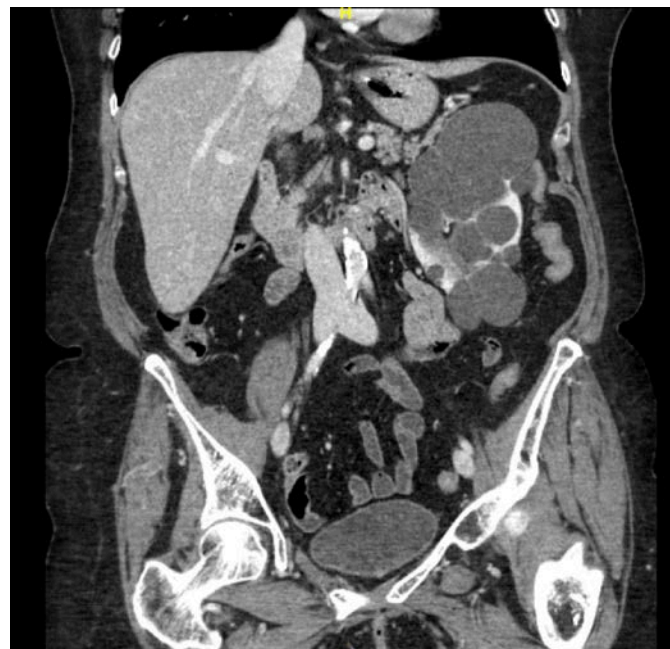

Figure 1: Coronal CT image demonstrating left kidney with multiple cysts involving the entire kidney and enlarged appearance.

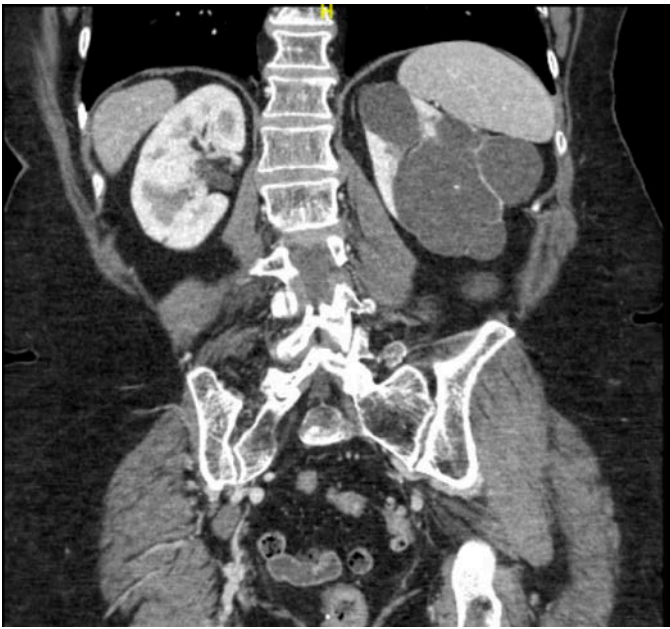


Figure 2: Deeper cross-section of CT imaging showing difference in appearance between the normal appearing right kidney and the enlarged, cystic left kidney.

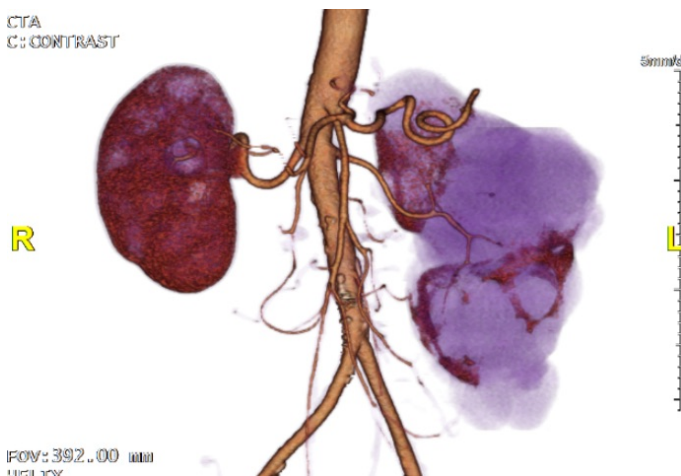


Figure 3: Three-dimensional constructed image of unilateral renal cystic disease in our patient

Discussion

Unilateral renal cystic disease is a rare entity characterized by multiple cysts with intervening normal parenchyma in one kidney or a portion of one kidney. It mimics autosomal dominant polycystic kidney disease (ADPKD) both morphologically and microscopically. Unlike ADPKD, patients do not have either a genetic background or progressive decline in renal function.

The pathogenesis is unknown but may involve a somatic mutation in the involved parenchyma.^{4,5}

Most of the time, unilateral renal cystic disease is incidentally found. Clinical presentation may include hypertension, hematuria, flank pain or flank mass.^{2,6} On CT imaging, there is normal enhancement of the intervening parenchyma.³ Renal function is typically preserved as in this case.^{3,4} However, there are cases where reported kidney impairment may be present but not at a glomerular filtration rate (GFR) less than 30 mL/min.⁵

Unilateral renal disease is benign, nonfamilial, nonprogressive, nonencapsulated, and not associated with cysts or malformations in other organs, which distinguishes it from other kidney cystic diseases like ADPKD, multicystic (dysplastic) kidney disease, tuberous sclerosis, von Hippel-Lindau disease and cystic neoplasm like multilocular cystic nephroma, cystic renal cell carcinoma, or cystic Wilm’s tumor.^{2,3,5}

Confusion exists in prior reports in differentiating between unilateral renal cystic disease and a unilateral form of autosomal dominant polycystic kidney disease since the two entities can appear identical both histologically and radiologically. It is possible to distinguish the two by the absence of family history, non-progression to end stage kidney disease and absence of characteristic abnormalities in other organ systems.^{2,5}

The contralateral unaffected kidney in unilateral renal cystic disease may occasionally show a few simple cysts as was the situation with our patient. It has been reported that unilateral disease may evolve into bilateral disease.⁶

Long term follow-up and serial imaging is required to confirm the diagnosis of unilateral renal cystic disease. To make the diagnosis of unilateral renal cystic disease and to rule out ADPKD, it is necessary to obtain renal ultrasound imaging in multiple generations.² However, as in this case, it may be difficult to coordinate such imaging in family members.

Our case highlights unilateral localization, negative family history, no deterioration in renal function, and the absence of cysts or malformations in other organs confirming the diagnosis.

REFERENCES

1. **Levine E, Huntrakoon M.** Unilateral renal cystic disease: CT findings. *J Comput Assist Tomogr.* 1989 Mar-Apr; 13(2):273-6. PubMed PMID: 2925913.
2. **Glassberg KI.** Unilateral renal cystic disease. *Urology.* 1999 Jun;53(6):1227-8. Review. PubMed PMID: 10367859.
3. **Choh NA, Rashid M.** Unilateral renal cystic disease. *Indian J Nephrol.* 2010 Apr;20(2):116-7. doi: 10.4103/0971-4065.65310. PubMed PMID: 20835331; PubMed Central PMCID: PMC2931128.
4. **Baradhi KM, Abuelo GJ.** Unilateral renal cystic disease. *Kidney Int.* 2012 Jan;81(2):220. doi: 10.1038/ki.2011.343. PubMed PMID: 22205432.

5. **Smyth B, Coleman P.** Localized cystic disease of the kidney: case report and review of the literature. *CEN Case Rep.* 2014 Nov;3(2):198-201. doi: 10.1007/s13730-014-0117-2. Epub 2014 Mar 17. PubMed PMID: 28509198; PubMed Central PMCID: PMC5411567.
6. **Hwang DY, Ahn C, Lee JG, Kim SH, Oh HY, Kim YY, Lee ES, Han JS, Kim S, Lee JS.** Unilateral renal cystic disease in adults. *Nephrol Dial Transplant.* 1999 Aug;14(8):1999-2003. Review. PubMed PMID: 10462284.