

CLINICAL VIGNETTE

Eosinophilic Colitis

Rajinder Kaushal, MD and Michael G. Quon, MD

Eosinophilic colitis (EC) is one of the eosinophilic gastrointestinal disorders (EGID). EGID can be classified into eosinophilic esophagitis, eosinophilic gastritis, eosinophilic gastroenteritis, and eosinophilic colitis. EGID are inflammatory disorders in which there is eosinophilic infiltration of the gastrointestinal tract without any known cause. We describe a case of EC and review its pathogenesis, symptoms, diagnosis, complications, treatment and prognosis.

Case

A 67-year-old female with a history of irritable bowel syndrome with constipation for over 30 years was seen for mucus in the stools and incontinence of mucus for several months. She denied any incontinence of stool, abdominal cramping or blood in the stools. There was no recent change of bowel habits. Approximately 2 years before the office visit she had been treated for *Clostridium difficile* infection and a recent stool test for *Clostridium difficile* was negative.

Her past medical history was significant for essential hypertension, hypothyroidism, right vocal cord paralysis, urticaria pigmentosa in her twenties and allergic rhinitis. Her current medications included levothyroxine, losartan, and multi-vitamins. Her last colonoscopy was over 11 years ago without biopsies. Physical examination was unremarkable. Her white cell count was 8,100 with 13.8 % eosinophils. Stool tests were negative for ova and parasites. A colonoscopy was performed. Except for a diminutive ascending colon polyp, colonoscopy to terminal ileum was normal (Figures 1, 2). Random terminal ileum biopsies were normal but random right and left colon biopsies revealed over 100 eosinophils in each high power field (Figures 3, 4) establishing a diagnosis of eosinophilic colitis.

During a post procedure follow up visit, patient stated that since her colonoscopy she no longer had mucus incontinence or mucus in the stools. Diagnosis of eosinophilic colitis, its symptoms, treatment and complications were discussed with the patient. Citing her right vocal cord paralysis, patient refused to have any additional work up including an endoscopy for esophageal, gastric and duodenal biopsies.

Discussion

EC is the rarest type of EGID with a prevalence of approximately 3 per 100,000 population. It affects both adults and children. Pathogenesis of EC is unknown though it is frequently

associated with other allergic conditions such as allergic rhinitis, asthma and eczema. Some infants may have milk-soy protein intolerance mimicking EC. In EC eosinophilic infiltration can be segmental or pan-colonic and may involve mucosal, muscular or subserosal layer.¹ There are no distinct clinical features that differentiate EC from other types of EGID. Patients may be asymptomatic. Mucosa predominant EC can present with diarrhea and protein losing enteropathy, with transmural disease with colonic wall thickening and features of acute intestinal obstruction, intussusception, cecal volvulus or even perforation. Subserosal disease can cause eosinophilic ascites.^{2,3} Other symptoms include abdominal pain, nausea, vomiting, difficulty feeding and/or gaining weight, poor growth and weight loss, bloody diarrhea, malnutrition and fatigue.

Eosinophilic infiltration of the colon can also be present in many other conditions including parasitic infections, inflammatory bowel disease, drug-induced colitis, allogeneic bone marrow transplant, eosinophilic granulomatosis with polyangiitis (Churg-Strauss syndrome), malignancy, and hypereosinophilic syndrome. These conditions should be excluded before making a diagnosis of EC. There is no involvement of other organs in EC. A detailed history should be obtained, especially history of all prescribed and over the counter medications as well as nutritional supplements. History of any allergic conditions such as allergic rhinitis, asthma and eczema should also be documented.

Patients with EC may have peripheral eosinophilia and their serum immunoglobulin E levels may be elevated. Radiological study findings are nonspecific and may reveal thickening, nodularity and narrowing of colon as well as ascites. Diagnosis of EC is confirmed by presence of eosinophilic infiltration of colon on biopsy and/or eosinophilic ascitic fluid. There are no established criteria for ascitic fluid eosinophilia but eosinophil counts of up to 88 percent have been reported in eosinophilic ascites.⁴ Eosinophils are normally present in colon. However, more than 100 eosinophils per high power field (HPF) in right colon, more than 84 eosinophils per HPF in transverse and descending colon and more than 64 eosinophils per HPF in rectum and sigmoid colon are considered diagnostic of EC.⁵ Colonoscopy findings may reveal a normal or hyperemic mucosa with or without nodularity and ulceration. Multiple biopsies should be taken from terminal ileum and different segments of colon. In muscular and subserosal disease, the mucosal biopsies may be normal and a full thickness biopsy may be necessary.

Elimination or elemental diet should be tried in patients who have EC associated with eosinophilic gastroenteritis. In patients who do not respond to elimination or elemental diet, prednisone 20-40 mg daily should be used. Prednisone should be tapered off as soon as symptoms improve. Aim of treatment is symptomatic relief and not elimination of eosinophilic infiltration. In recurrent disease, small dose of prednisone may have to be used long term.^{6,7} Other treatments used for EC include Cromolyn sodium,⁸ montelukast,⁹ suplatast tosilate,¹⁰ Ketotifen (a second-generation H1-antihistamine not available in the US)¹¹ and Omalizumab an anti-Immunoglobulin E (IgE) monoclonal antibody.

Natural history of EC is unknown. Patients may remain asymptomatic, have intermittent symptoms or have progressive disease resulting in stricture formation and perforation. Patient response to treatment is also unpredictable. Patients may stay in remission after one treatment, may have intermittent flares or may need long-term maintenance treatment. EC that develops in infancy carries a good prognosis. It usually resolves spontaneously, sometimes within a few days. After a few years, these young children can even tolerate the implicated foods. In contrast, adults with EC tend to have more chronic presentation with periods of activity and remission.

Summary

Primary EC is a rare disorder. It is a mild, food-related disease in infants, but a chronic disease in adults. Symptoms depend on the colonic layer being predominantly infiltrated with eosinophils. Diagnosis of primary EC is based on multiple colonic biopsies and elimination of secondary causes. Treatment of EC with eosinophilic gastroenteritis is with elimination/elemental diets. Patients who do not respond to diet should be given a trial of prednisone. Other treatments used for EC include Cromolyn sodium, montelukast, suplatast tosilate, Ketotifen (a second-generation H1-antihistamine not available in the US) and Omalizumab an anti-Immunoglobulin E (IgE) monoclonal antibody. Infants with EC have a good prognosis with complete resolution of disease but adults may have more chronic relapsing and remitting disease.

Since this patient was asymptomatic, no treatment was offered to her at this time. She was educated on EC advised to keep routine follow up office appointments.

Figures

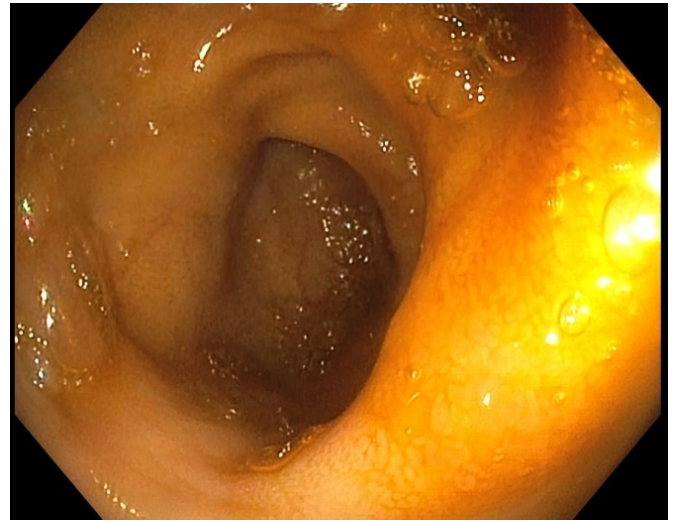


Figure 1 Terminal ileum

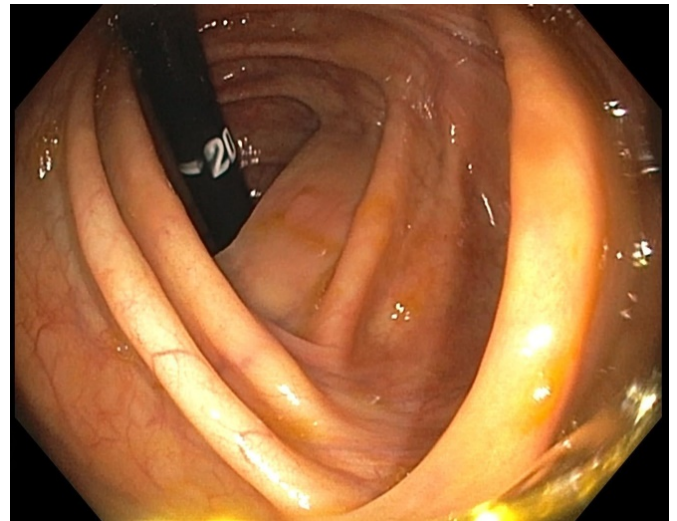


Figure 2 Ascending colon

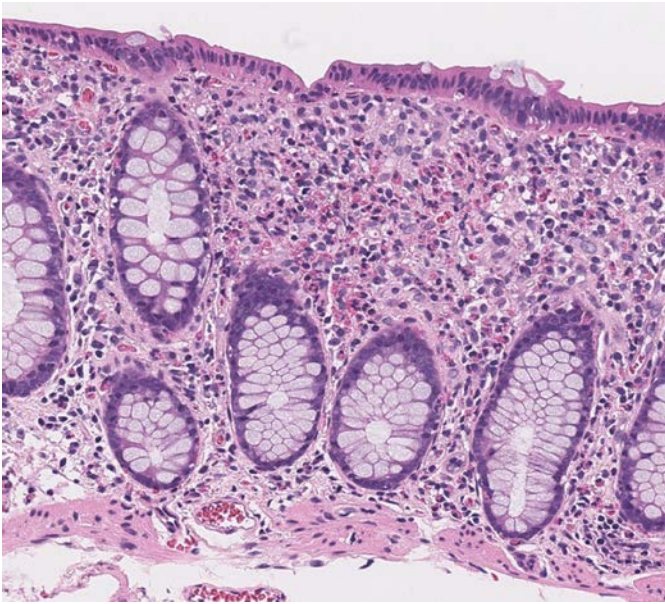

Figure 3 Right colon

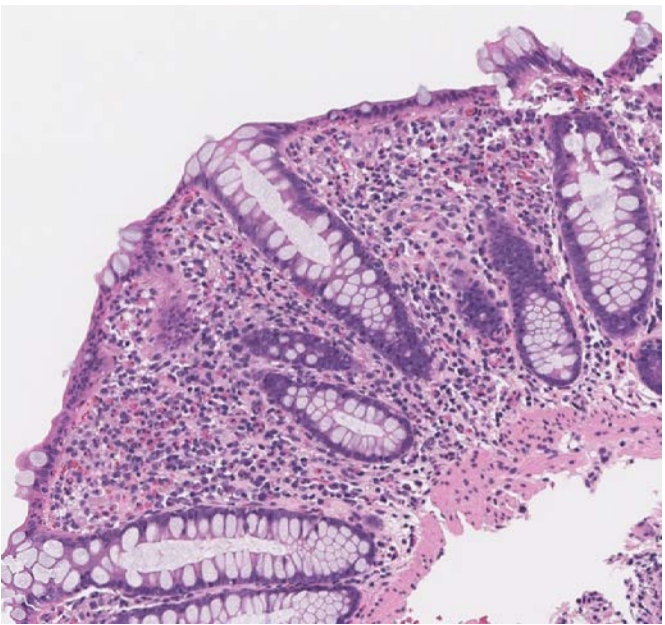


Figure 4 Left colon

REFERENCES

1. **Rothenberg ME.** Eosinophilic gastrointestinal disorders (EGID). *J Allergy Clin Immunol.* 2004 Jan;113(1):11-28; quiz 29. Review. PubMed PMID: 14713902.
2. **Velchuru VR, Khan MA, Hellquist HB, Studley JG.** Eosinophilic colitis. *J Gastrointest Surg.* 2007 Oct;11(10):1373-5. PubMed PMID: 17849167.
3. **Kravis LP, South MA, Rosenlund ML.** Eosinophilic gastroenteritis in the pediatric patient. *Clin Pediatr (Phila).* 1982 Dec;21(12):713-7. PubMed PMID: 7140122.

4. **Klein NC, Hargrove RL, Sleisenger MH, Jeffries GH.** Eosinophilic gastroenteritis. *Medicine (Baltimore).* 1970 Jul;49(4):299-319. PubMed PMID:5426746.
5. **Collins MH.** Histopathologic features of eosinophilic esophagitis and eosinophilic gastrointestinal diseases. *Gastroenterol Clin North Am.* 2014 Jun;43(2):257-68. doi: 10.1016/j.gtc.2014.02.007. Epub 2014 Mar 19. PubMed PMID: 24813514.
6. **Chen MJ, Chu CH, Lin SC, Shih SC, Wang TE.** Eosinophilic gastroenteritis: clinical experience with 15 patients. *World J Gastroenterol.* 2003 Dec;9(12):2813-6. PubMed PMID: 14669340; PubMed Central PMCID: PMC4612059.
7. **Lee CM, Changchien CS, Chen PC, Lin DY, Sheen IS, Wang CS, Tai DI, Sheen-Chen SM, Chen WJ, Wu CS.** Eosinophilic gastroenteritis: 10 years experience. *Am J Gastroenterol.* 1993 Jan;88(1):70-4. PubMed PMID: 8420276.
8. **Pérez-Millán A, Martín-Lorente JL, López-Morante A, Yuguero L, Sáez-Royuela F.** Subserosal eosinophilic gastroenteritis treated efficaciously with sodium cromoglycate. *Dig Dis Sci.* 1997 Feb;42(2):342-4. PubMed PMID: 9052516.
9. **Schwartz DA, Pardi DS, Murray JA.** Use of montelukast as steroid-sparing agent for recurrent eosinophilic gastroenteritis. *Dig Dis Sci.* 2001 Aug;46(8):1787-90. PubMed PMID: 11508684.
10. **Shirai T, Hashimoto D, Suzuki K, Osawa S, Aonahata M, Chida K, Nakamura H.** Successful treatment of eosinophilic gastroenteritis with suplatast tosilate. *J Allergy Clin Immunol.* 2001 May;107(5):924-5. PubMed PMID: 11344364.
11. **Melamed I, Feanny SJ, Sherman PM, Roifman CM.** Benefit of ketotifen in patients with eosinophilic gastroenteritis. *Am J Med.* 1991 Mar;90(3):310-4. PubMed PMID: 2003512.

Submitted May 4, 2019