

CLINICAL VIGNETTE

Ethylene Glycol Intoxication

Reza Khorsan, MD and Carl Schulze, MD

A 50 year-old male with an unknown past medical history found down on the sidewalk is brought in by ambulance. On arrival, he is confused, complains of abdominal pain, nausea and emesis. He reports drinking a pint of vodka a day for the past several months. He denies drinking anti-freeze. His physical exam is notable for a temperature of 36.4 C, BP 134/72 mmHg, pulse of 100 bpm, RR of 18 bpm, saturating 98% on room air. He appears disheveled and somnolent. HEENT are notable for poor dentition, CV with tachycardia and regular rhythm. S1 and S2 normal. Lungs are clear to auscultation bilaterally. His abdomen has normal bowel sounds and is diffusely tender to palpation, without guarding. He is uncooperative with the neurological exam but is moving all extremities. Laboratory studies were significant for serum sodium 137 mmol/L, potassium is 5.1 mmol/L, total CO₂ of 6 mmol/L, BUN of 75 mg/dL, creatinine of 3.9 mg/dL, calcium of 8.9 mg/dL, and glucose of 127 mg/dL. Calculated serum anion-gap is 43. Measured osmolality is 343 mOsm/kg, calculated osmolal gap is 35 mOsm/kg, serum ethylene glycol level is pending though eventually returns at 6 mg/dL, ethyl alcohol negative, pH 7.1. A summary of the acid base and osmolality results can be seen in Figure 1. In the ED he receives 2 liters of NS, and vancomycin and piperacillin/tazobactam. He is admitted to the ICU and undergoes emergent hemodialysis. His total CO₂ improves to 25 mmol/L the next morning, but decreases again in the afternoon to 16 mmol/L. His serum calcium drops to 7.7 mg/dL. He undergoes a second session of hemodialysis on hospital day 2. On the third day total CO₂ improved to 19 mmol/L, but he continues to have an anion-gap of 32. On the 4th day of hospitalization, his serum total CO₂ drops to 8 mmol/L and serum anion gap increases to 43. Repeat ethylene glycol level is <5, but his acetone level returns as 93 mg/dL. He is emergently intubated for respiratory distress and undergoes his 3rd session of hemodialysis. On the fifth day of hospitalization, he continues to have an elevated anion gap metabolic acidosis. His serum acetone level increases to 120 mg/dL. Gama-Hydroxybutyric acid level is not detectable. He requires ongoing hemodialysis for 4 more weeks and is discharged to an outpatient hemodialysis facility after 28 days in the hospital with no recovery of renal function.

Toxic alcohols and ethanol lead to similar CNS presentations though the former also cause additional toxicity due to downstream metabolites that can result in renal failure, systemic blindness, more severe central nervous system (CNS) depression, and electrolyte abnormalities.¹ Methanol is a common contaminant in crudely distilled alcohol (*E.g.*, moonshine)² and

is also a biological toxin found in the venom of the genus *Solinepsis Invicta Buren* (fire ants).³ The ingestion of methanol either inadvertently from crudely distilled liquor, purposefully as a suicide attempt, or as an alcohol substitute frequently results in severe metabolic acidosis, obtundation, and can result in irreversible blindness if not quickly diagnosed and treated.¹ The toxicity of methanol is due to the conversion of methanol via alcohol dehydrogenase into formic acid and formate's tendency to concentrate in and damage the retinal cells.⁴ A high osmolal gap and anion gap can occur depending on how long after the ingestion these levels are measured (Figure 2).

Ethylene glycol (EG), commonly found in anti-freeze and as an alcohol substitute, is also considered a toxic alcohol. EG metabolites are responsible for the non CNS systemic toxicity. After EG is ingested, it is metabolized to glycolaldehyde, glycolic acid, glyoxalate, and oxalate.⁵ EG has a peak concentration 1-3h after ingestion, and has a half-life of 3h but this can be prolonged several-fold by the presence of ethanol or fomepizole.⁵ EG itself causes an elevated osmolar gap and is nontoxic. The toxicity comes from glycolic acid and oxalate. Glycolate causes the anion gap metabolic acidosis⁶ and might also contribute to acute kidney injury.⁵ The risk of acute kidney injury (AKI) correlates strongly with the serum level of glycolate, and the latter correlates strongly with the anion gap.⁷ Oxalate causes the AKI by deposition of calcium oxalate crystals in the renal parenchyma and urinary collecting system and directly causing ATN of PCT cells.⁸ In EG intoxication, CAOX precipitates in other organs as well, resulting in hypocalcemia and possibly organ dysfunction.⁵ Unfortunately, examining the urine for Ca-Ox crystals or for fluorescein dye is not sensitive to be useful in the diagnosis.⁹

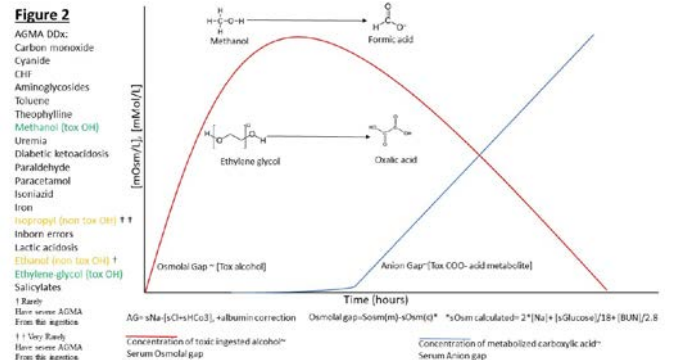
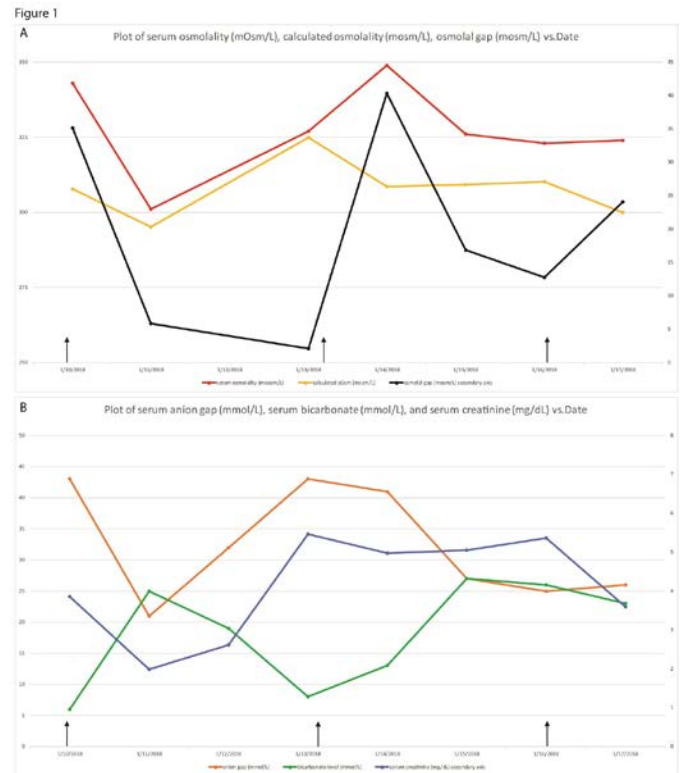
Treatment of toxic alcohol ingestion focuses on preventing formation of active metabolites and facilitating their elimination after they have formed. The most important strategy to prevent metabolite formation in methanol and EG ingestions is inhibition of alcohol dehydrogenase with either ethanol or 4-methylpyrazole (Fomepizole).^{5,10} The latter is preferred due to a favorable side effect profile though is more expensive.⁵ In EG intoxication, other metabolites also cause toxicity so their formation is also prevented. Other measures include avoidance of calcium supplementation due to the risk of calcium oxalate precipitation and supplementation of pyridoxine and thiamine which promote metabolism of glycolate and oxalate into nontoxic byproducts (*eg* pyridoxine converts glycolic acid to glycine).^{5,8,10} Supportive measures include

protection of the airway, correction of volume depletion, and bicarbonate therapy to maintain pH >7.3.^{5,10,11}

Hemodialysis (HD) is needed when active metabolites lead to toxicity. Suggested criteria for HD in EG intoxication are severe acidosis (pH <7.25), acute kidney injury, or high ethylene glycol level (>50 mg/dL) (5). Solute removal in dialysis depends upon the molecular size, volume of distribution (VD), protein binding, and properties of the dialysis apparatus.¹² Alcohols have a VD the same as water (0.6L/kg) and like any solutes with a VD greater than plasma, can rebound after a dialysis treatment.¹³ Glycolate, the most important target of dialysis treatment in EG intoxication, is a small molecule and is not protein-bound, so is efficiently dialyzed. Case reports have shown clearances of about 140 mL/min at blood flows of 200mL/min.⁶ However, the large VD (0.6-0.8 L/kg) of both ethylene glycol and glycolate^{5,6} make them prone to redistribute after a dialysis treatment resulting in a rebound of toxicity, which likely occurred in this patient. Fomepizole can be used concomitantly with hemodialysis but it must be prescribed as a continuous drip during dialysis as it is removed by hemodialysis.¹⁰

Appropriate treatment depends upon prompt diagnosis, which requires a high index of suspicion. Blurry vision, blindness, severe CNS coma, calcium oxalate crystals in urine, and a severe anion gap metabolic acidosis can suggest a toxic alcohol ingestion though are not sufficiently sensitive or specific to confirm the diagnosis. The presence of some or all of the above findings should trigger a clinician to look for an osmolal gap. The finding of an osmolar gap of greater than 10-20 mosm between measured and calculated serum osmolality (see Figure 1 for formulas) should increase concern for the diagnosis, though it is necessary to correct the osmolar gap for blood ethanol level.¹⁴ Indeed, this patient had a complex clinical picture with history of coingestion of ethanol and EG. He experienced significant rebounds of anion gap metabolic acidosis and elevated osmolar gap after two full hemodialysis treatments, which resulted in a medical emergency call. These events are most likely a consequence of the large VD of glycolate, leading to redistribution of the molecule with recurrence of toxicity after the first two dialysis sessions. He was also exposed to excess calcium supplementation as he was severely hypocalcemic.

In summary, patients with the combination of comatose state, severe metabolic acidosis with elevated anion gap, osmolal gap, and AKI, EG intoxication should be considered. The clinical manifestations of toxic alcohol ingestion are nonspecific, though the increasing availability of direct measurement of the toxic alcohol should simplify the diagnosis and avoid delays in appropriate treatment versus reliance on surrogate levels like serum osmolality or serum osmolal gap.⁸



REFERENCES

- Kraut JA, Mullins ME.** Toxic Alcohols. *N Engl J Med.* 2018 Jan 18;378(3):270-280. doi: 10.1056/NEJMra1615295. Review. PubMed PMID: 29342392.
- Shafi H, Imran M, Usman HF, Sarwar M, Tahir MA.** Eight fatalities due to drinking methanol-tainted alcohol in Pakistan: A case report. *Egyptian J Forensic Sciences.* 2016 6(4):515-19.
- Chen J, Rashid T, Feng G.** Toxicity of formic acid to red imported fire ants, *Solenopsis invicta* Buren. *Pest Manag Sci.* 2012 Oct;68(10):1393-9. doi: 10.1002/ps.3319. Epub 2012 Jun 1. PubMed PMID: 22674812.
- Jacobsen D, McMartin KE.** Methanol and ethylene glycol poisonings. Mechanism of toxicity, clinical course, diagnosis and treatment. *Med Toxicol.* 1986 ep-Oct;1(5):309-34. Review. PubMed PMID: 3537623.

5. **Barceloux DG, Krenzelok EP, Olson K, Watson W.** American Academy of Clinical Toxicology Practice Guidelines on the Treatment of Ethylene Glycol Poisoning. Ad Hoc Committee. *J Toxicol Clin Toxicol.* 1999;37(5): 537-60. PubMed PMID: 10497633.
6. **Jacobsen D, Ovrebo S, Ostborg J, Sejersted OM.** Glycolate causes the acidosis in ethylene glycol poisoning and is effectively removed by hemodialysis. *Acta Med Scand.* 1984;216(4):409-16. PubMed PMID: 6516909.
7. **Porter WH, Rutter PW, Bush BA, Pappas AA, Dunnington JE.** Ethylene glycol toxicity: the role of serum glycolic acid in hemodialysis. *J Toxicol Clin Toxicol.* 2001;39(6):607-15. PubMed PMID: 11762669.
8. **McMartin K.** Are calcium oxalate crystals involved in the mechanism of acute renal failure in ethylene glycol poisoning? *Clin Toxicol (Phila).* 2009 Nov;47(9):859-69. doi: 10.3109/15563650903344793. Review. PubMed PMID: 19852621.
9. **Winter ML, Snodgrass WR.** Urine fluorescence in ethylene glycol poisoning. *N Engl J Med.* 2007 May 10; 356(19):2006; author reply 2006-7. PubMed PMID: 17494942.
10. **Mégarbane B.** Treatment of patients with ethylene glycol or methanol poisoning: focus on fomepizole. *Open Access Emerg Med.* 2010 Aug 24;2:67-75. doi:10.2147/OAEM.S5346. eCollection 2010. Review. PubMed PMID: 27147840; PubMed Central PMCID: PMC4806829.
11. **Kraut JA, Kurtz I.** Toxic alcohol ingestions: clinical features, diagnosis, and management. *Clin J Am Soc Nephrol.* 2008 Jan;3(1):208-25. Epub 2007 Nov 28. Review. PubMed PMID: 18045860.
12. **Daugirdas JT.** Physiologic Principles and Urea Kinetic Modeling. In: Daugirdas J, Blake P, Ing T. Handbook of Dialysis, 4th Ed. 2007: Lippincott, Williams, and Wilkins. PP 25-28
13. **Winchester JF et al.** Use of Dialysis and Hemoperfusion in Treatment of poisoning. In: Daugirdas J, Blake P, Ing T. Handbook of Dialysis, 4th Ed. 2007: Lippincott, Williams, and Wilkins. PP 300-310.
14. **Purssell RA, Pudek M, Brubacher J, Abu-Laban RB.** Derivation and validation of a formula to calculate the contribution of ethanol to the osmolal gap. *Ann Emerg Med.* 2001 Dec;38(6):653-9. PubMed PMID: 11719745.