

CLINICAL VIGNETTE

Kikuchi-Fujimoto Disease Presenting as Unilateral Axillary Lymphadenopathy

Richard Hwang and Vinh Lam, MD

Background

Kikuchi-Fujimoto disease (KFD), also known as histiocytic necrotizing lymphadenitis, was first described in Japan in 1972 and is a rare, benign self-limiting cause of lymphadenopathy.^{1,2} KFD usually presents as localized lymphadenopathy involving the cervical lymph nodes, and may be associated with fevers, night sweats, fatigue, and arthralgia.³ The presentation of KFD can be indistinguishable from malignant lymphoma or systemic lupus erythematosus (SLE), and histological diagnosis is typically required.^{4,5} To our knowledge, KFD presenting as unilateral axillary lymphadenopathy has only been described in a small number of case reports, and only in female patients without B symptoms.⁶⁻⁹ We report an uncommon presentation of KFD as unilateral axillary lymphadenopathy with B symptoms in a young Hispanic male.

Case Presentation

A 19-year-old Hispanic male with no significant past medical history presented to the hospital for evaluation of an enlarging right axillary mass. The mass first appeared as a small, tender axillary nodule one month prior to presentation and was progressively increasing in size. Two weeks after the initial appearance of the mass, the patient began experiencing intermittent fevers, night sweats, and weight loss.

The patient was asymptomatic prior to the appearance of the mass and denied any recent illness/infection, fevers, chills, upper respiratory symptoms, sore throat, sick contacts, or recent travel. Physical examination revealed a soft, mobile, tender 7x6 cm right axillary mass without overlying skin changes. There was no evidence of cervical, supraclavicular, inguinal, or contralateral axillary lymphadenopathy. The remainder of the patient's physical exam was unremarkable. The patient was hospitalized for expedited work-up of the axillary mass. During hospitalization, the patient was intermittently febrile up to a maximum temperature of 39.8°C. The patient's fevers were minimally responsive to anti-pyretics such as ibuprofen and acetaminophen.

Laboratory tests were notable for thrombocytopenia and an elevated LDH (>600 U/L) (see Table 1). A workup for possible infectious causes of the patient's lymphadenopathy was performed, which was notable for positive EBV IgG serologies. However, the patient denied any recent history of symptoms suggestive of infectious mononucleosis. The remainder of the patient's work-up for infectious etiologies (TB, CMV, HIV,

HBV, HCV, *Bartonella spp*, *Coccidioides*, *Cryptococcus*) was negative. CT chest/abdomen/pelvis revealed several enlarged right axillary lymph nodes, the largest measuring 2.1cm (see Figure 1).

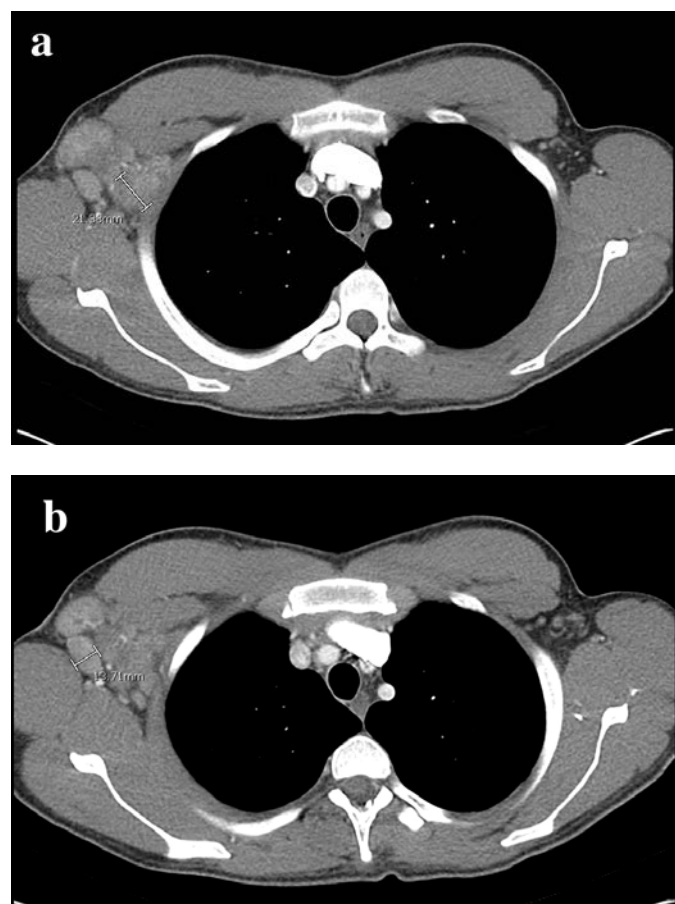


Figure 1: CT thorax showed unilateral enlarged (a) 2.1cm, and (b) 1.3cm right axillary lymph nodes.

Core biopsy of the axillary mass was inconsistent with malignant lymphoma, revealing patchy necrosis, apoptosis, and a lymphohistiocytic background without evidence of monotypic B cell proliferation. Given the high suspicion for malignant lymphoma and concern for a false-negative core biopsy, an excisional biopsy of the mass was performed. Histopathology of the excisional biopsy revealed large areas of confluent

necrosis with focal residual reactive follicles and an absence of neutrophils, with necrotic areas rimmed by sheets of histiocytes. IHC was performed using the following antibodies: CD3, CD4, CD5, CD8, CD10, CD15, CD20, CD30, CD68, CD123, PAX5, BCL2, Ki67, ALK1. Flow cytometry was negative for monotypic B cells or T cell aberrancy, ruling out malignant lymphoma. Tissue culture and stains (acid fast, PAS, GMS) were negative for organisms. EBV in situ hybridization for EBV RNA was negative. Based on the histologic and immunohistologic findings, the patient was diagnosed with KFD.

Within 24 hours after excisional biopsy, the patient reported significant subjective improvement in constitutional symptoms. The patient was discharged with ibuprofen and acetaminophen for supportive treatment of pain and fevers. At two-week follow-up, the patient's right axillary lymphadenopathy had decreased in size to 3x3cm. At six-week follow-up, the patient reported rare night sweats and resolution of fevers and weight loss. The lymphadenopathy had further decreased in size to 1x1cm. At four months, the patient's lymphadenopathy and constitutional symptoms had completely resolved.

Discussion

KFD is a rare, self-limiting cause of lymphadenopathy more commonly seen in young adult females in East Asia. The prevalence of the disorder is unknown, and a relatively limited number of cases have been described in the United States.^{10,11} This patient's presentation of KFD as isolated unilateral axillary lymphadenopathy with B symptoms is a rare presentation of KFD. KFD presenting as isolated unilateral axillary lymphadenopathy has only been described in isolated case reports.⁶⁻⁹ However, the patients in these cases were all females without constitutional symptoms, which was more concerning for breast malignancy. In contrast, our patient's presentation was highly concerning for malignant lymphoma and highlights the difficulty in distinguishing KFD from other causes of lymphadenopathy.

KFD classically presents as a constellation of signs and symptoms that can resemble malignant lymphoma, SLE, and bacterial lymphadenitis. In approximately 95% of cases, KFD presents as localized lymphadenopathy involving the cervical lymph nodes.¹⁰ Constitutional symptoms, such as fever, chills, night sweats, fatigue, loss of appetite, and weight loss are present in over 80% of patients.³ Approximately 30% of patients may also have mucocutaneous manifestations, such as maculopapular rash, malar rash, oral ulcers, and alopecia.¹² Common laboratory findings include elevated ESR and CRP, leukopenia, anemia, elevated transaminases, elevated LDH, and ANA positivity.^{3,10}

The pathogenesis of KFD is poorly understood, but most studies propose a hyperimmune response to an infectious agent or an autoimmune-mediated etiology.^{10,13} EBV has been implicated based on the presence of EBV RNA or DNA in the lymph nodes of some patients with KFD, while other studies suggest a link with HHV-6.^{14,15} Although this patient had

positive EBV IgG serologies, in situ hybridization of the patient's biopsy tissue for EBV RNA was negative. Moreover, this patient denied any known history of EBV mononucleosis or other symptoms suggestive of a viral infection prior to the onset of axillary lymphadenopathy. Therefore, it remains unclear whether this patient's positive EBV serology was merely a coincidental finding.

The differential diagnosis of axillary lymphadenopathy in adolescents typically includes infectious, oncologic, and autoimmune etiologies. Because the clinical presentation of KFD is variable and often overlaps with these other causes of lymphadenopathy, diagnosis of KFD usually requires histologic analysis of an affected lymph node. Characteristic findings include paracortical foci of necrosis and histiocytic cellular infiltrate.¹⁶ Immunohistologic studies show a predominance of CD68+ histiocytes and plasmacytoid monocytes, with absence or sparse neutrophils.¹⁷ Final histologic diagnosis of KFD is often delayed with a median time of diagnosis of 1.6 months, particularly when KFD is misdiagnosed as an infectious etiology based on clinical symptoms.³

As KFD is a self-limiting disease, treatment is typically supportive with analgesics and anti-pyretics. Corticosteroids and hydroxychloroquine are often used in more severe or prolonged cases, although there is limited evidence regarding the effectiveness of these treatments for KFD.¹⁰ Up to one third of patients may receive empiric antibiotic therapy for presumed bacterial adenitis prior to diagnosis, highlighting the importance of timely histologic diagnosis to spare patients from inappropriate treatments.³ Tissue biopsy must be performed for diagnostic purposes, but can also be therapeutic as seen in this patient, who experienced subjective improvement in his constitutional symptoms after excisional biopsy. Overall, KFD has a favorable prognosis with complete resolution of symptoms in the majority of patients within 6 months.¹⁰ However, up to 20% of patients may experience prolonged or recurrent KFD, particularly those with positive ANA, and thus patients should be followed to ensure complete resolution of symptoms.^{3,18}

Conclusion

This case report describes an uncommon presentation of KFD as isolated unilateral axillary lymphadenopathy with B symptoms in a young adult Hispanic male. KFD most often presents as localized cervical lymphadenopathy and only a small number of cases presenting as isolated unilateral axillary lymphadenopathy have been described. Given the presence of B symptoms, this patient's presentation of KFD overlapped significantly with a common presentation of malignant lymphoma, and highlights the challenge in differentiating between malignant lymphoma and KFD. Although KFD is a rare cause of lymphadenopathy, it should be considered in the differential diagnosis of lymphadenopathy. KFD is a benign, self-limiting condition that requires timely histologic diagnosis to spare patients from unnecessary treatment.

Table 1. Selected Laboratory Values at Initial Presentation.

Laboratory Test	Result	Reference Range
WBC	4.4 x 10 ³ / μL	3.8 – 10.9 x 10 ³ / μL
RBC	4.88 x 10 ⁹ / μL	4.3 – 5.8 x 10 ⁹ / μL
Hgb	14.6 g/dL	13.6 – 17.3 g/dL
Hct	43.0%	39.8 – 50.7%
Platelet	109 x 10³ / μL	141 – 401 x 10³ / μL
Alk Phos	65 U/L	38 – 126 U/L
AST	40 U/L	15 – 41 U/L
ALT	26 U/L	14 – 54 U/L
Bilirubin (Total)	1.0 mg/dL	0.1 – 1.2 mg/dL
Bilirubin (Direct)	0.2 mg/dL	0.1 – 0.4 mg/dL
Haptoglobin	293 mg/dL	36 – 195 mg/dL
Lactate dehydrogenase	612 U/L	98 – 192 U/L
HIV Antibody-Antigen Screen	Nonreactive	-
QuantiFERON TB	Negative	-
EBV VCA IgM	Negative	-
EBV VCA IgG	Positive	-
EBV Nuclear Antigen IgG	Positive	-
CMV PCR	Negative	-
<i>Bartonella henselae</i> IgM	Negative	-
<i>Bartonella henselae</i> IgG	Negative	-

REFERENCES

1. **Kikuchi M.** Lymphadenitis showing focal reticulum cell hyperplasia with nuclear debris and phagocytosis. *Nihon Ketsueki Gakkai Zasshi.* 1972;35:379.
2. **Fujimoto Y, Kozima Y, Yamaguchi K.** Cervical subacute necrotising lymphadenitis. A new clinicopathological entity. *Naika.* 1972;20:920–7.
3. **Dumas G, Prendki V, Haroche J, Amoura Z, Cacoub P, Galicier L, Meyer O, Rapp C, Deligny C, Godeau B, Aslangul E, Lambotte O, Papo T, Pouchot J, Hamidou M, Bachmeyer C, Hachulla E, Carmoi T, Dhote R, Gerin M, Mekinian A, Stirnemann J, Charlotte F, Farge D, Molina T, Fain O.** Kikuchi-Fujimoto disease: retrospective study of 91 cases and review of the literature.

4. **Chamulak GA, Brynes RK, Nathwani BN.** Kikuchi-Fujimoto disease mimicking malignant lymphoma. *Am J Surg Pathol.* 1990 Jun;14(6):514-23. Review. PubMed PMID:2186643.
5. **Dorfman RF, Berry GJ.** Kikuchi's histiocytic necrotizing lymphadenitis: an analysis of 108 cases with emphasis on differential diagnosis. *Semin Diagn Pathol.* 1988 Nov;5(4):329-45. PubMed PMID: 3217625.
6. **Kovacs S, Friedman PD, Kuehn A.** Unilateral axillary adenopathy caused by Kikuchi-Fujimoto disease. *Breast J.* 2006 Jan-Feb;12(1):77-9. PubMed PMID: 16409593.
7. **Ohta K, Endo N, Kaizaki Y.** Axillary and intramammary lymphadenopathy caused by Kikuchi-Fujimoto disease mimicking malignant lymphoma. *Breast Cancer.* 2013 Jan;20(1):97-101. doi: 10.1007/s12282-009-0182-0. Epub 2009 Nov 27. PubMed PMID: 19943128.
8. **Nagaraju S, Vaishnav S, Burke LH, Norman EM.** Histiocytic necrotizing lymphadenitis (Kikuchi-Fujimoto disease) of axillary lymph nodes. *BMJ Case Rep.* 2015 Jan 5;2015. pii: bcr2014203776. doi: 10.1136/bcr-2014-203776. PubMed PMID:25564582; PubMed Central PMCID: PMC4289788.
9. **Mannu GS, Ahmed F, Cunnick G, Sheppard K.** A rare cause of axillary lymphadenopathy: Kikuchi's disease. *BMJ Case Rep.* 2014 Mar 7;2014. pii: bcr2013203100. doi: 10.1136/bcr-2013-203100. PubMed PMID: 24717860; PubMed Central PMCID: PMC3948011.
10. **Kucukardali Y, Solmazgul E, Kunter E, Oncul O, Yildirim S, Kaplan M.** Kikuchi-Fujimoto Disease: analysis of 244 cases. *Clin Rheumatol.* 2007 Jan;26(1):50-4. Epub 2006 Mar 15. PubMed PMID: 16538388.
11. **Deaver D, Naghashpour M, Sokol L.** Kikuchi-fujimoto disease in the United States: three case reports and review of the literature [corrected]. *Mediterr J Hematol Infect Dis.* 2014 Jan 1;6(1):e2014001. doi: 10.4084/MJHID.2014.001. eCollection 2014 Jan 1. Erratum in: *Mediterr J Hematol Infect Dis.* 2014;6(1):E2014023. PubMed PMID: 24455110; PubMed Central PMCID: PMC3894840.
12. **Mathew LM, Kapila R, Schwartz RA.** Kikuchi-Fujimoto disease: a diagnostic dilemma. *Int J Dermatol.* 2016 Oct; 55(10):1069-75. doi: 10.1111/ijd.13314. Epub 2016 May 21. Review. PubMed PMID: 27207311.
13. **Veer V, Lim A, Issing W.** Kikuchi-fujimoto disease: a case report and literature review. *Case Rep Otolaryngol.* 2012;2012:497604. doi: 10.1155/2012/497604. Epub 2012 Jul 26. PubMed PMID: 22953115; PubMed Central PMCID: PMC3420536.
14. **Chiu CF, Chow KC, Lin TY, Tsai MH, Shih CM, Chen LM.** Virus infection in patients with histiocytic necrotizing lymphadenitis in Taiwan. Detection of Epstein-Barr virus, type I human T-cell lymphotropic virus, and parvovirus B19. *Am J Clin Pathol.* 2000 Jun;113(6):774-81. PubMed PMID: 10874877.

15. **Dominguez DC, Torres ML, Antony S.** Is human herpesvirus 6 linked to kikuchi-fujimoto disease? The importance of consistent molecular and serologic analysis. *South Med J.* 2003 Mar;96(3):226-33. Review. PubMed PMID: 12659352.
16. **Tsang WY, Chan JK, Ng CS.** Kikuchi's lymphadenitis. A morphologic analysis of 75 cases with special reference to unusual features. *Am J Surg Pathol.* 1994 Mar;18(3):219-31. PubMed PMID: 8116791.
17. **Kuo TT.** Kikuchi's disease (histiocytic necrotizing lymphadenitis). A clinicopathologic study of 79 cases with an analysis of histologic subtypes, immunohistology, and DNA ploidy. *Am J Surg Pathol.* 1995 Jul;19(7):798-809. PubMed PMID: 7793478.
18. **Song JY, Lee J, Park DW, Sohn JW, Suh SI, Kim IS, Kim WJ, Kim MJ, Cheong HJ.** Clinical outcome and predictive factors of recurrence among patients with Kikuchi's disease. *Int J Infect Dis.* 2009 May;13(3):322-6. doi: 10.1016/j.ijid.2008.06.022. Epub 2009 Feb 8. PubMed PMID: 19208493.

Submitted April 29, 2018