

CLINICAL VIGNETTE

Symptomatic Glomangioma of the Trachea in a 33-Year-Old Man Initially Managed by Minimally Invasive Bronchoscopic Interventions

Chidinma Chima-Melton, MD

Case Presentation

A 33-year-old man presented with progressive dyspnea and hemoptysis for several months. His physical exam was unremarkable. Pulmonary function test demonstrated severe obstructive ventilatory defect with no significant post-bronchodilator response. Flow-volume loop suggested upper airway obstruction. CT revealed a large endotracheal mass, nearly completely occluding the lumen in a "ball-valve" type appearance (Figure 1).

Flexible bronchoscopy under general anesthesia, confirmed a mid-tracheal polypoid tumor (Figure 2), nearly completely occluding the lumen 5.5 cm below the vocal folds and 4cm above the carina. The lesion was 2.5 cm, very friable and arising from posterior membranous wall of trachea. The patient refused surgical resection and opted for bronchoscopic resection to avoid interruption of his graduate program.

Flexible bronchoscopy was performed under general anesthesia with snare electro-cauterization followed by argon electro-cauterization and forceps debridement of the luminal tumor. We were able to successfully excise the tumor with 80% patency.

Histological examination of viable cells demonstrated a sheet-like distribution, in a slightly organoid to clustered array, well developed vessels and a hyalinized wall. The cells had a high nuclear to cytoplasmic ratio, with delicate to slightly coarse nuclear chromatin distribution. Nucleoli were small and inconspicuous without mitoses.

The neoplastic cells showed the following immunohistochemistry profile:

Positive: smooth muscle actin; CD34 (vascular component), Ki-67 (2% proliferation).

Negative: CK-pan, CD56, calcitonin, synaptophysin, S100 protein, HMB45, neurofilament.

The intimate association of the glomus cells with the vascular component, placed the tumors in the glomangioma category.

The patient reported no dyspnea or hemoptysis following bronchoscopy, but underwent a repeat bronchoscopy 3 months later with further reduction of the tumor by argon electro-cauterization and laser.

Three months after the second bronchoscopy, he was asymptomatic and imaging demonstrated good control of the lesion. He

opted to have elective surgical resection in the subsequent year and continues to be followed closely.

Discussion

Glomus tumors are benign neoplasms that originate from smooth muscle often found in the subungual regions near thermoregulating arteriovenous anastomoses in glomus bodies. Glomus tumors can occasionally be seen in other organs including muscle, tendons, stomach, bones, the heart and very rarely the lungs.^{1,2} Four subtypes have been classified based on structural differences and on the relative proportions of glomus cells, vascular structures, and smooth muscle tissue in the tumor. Their relative frequencies are as follows: 75% are classic glomus tumors, 20% are glomangiomas, and the remaining few fall in the category of glomangiomyoma and oncocytic glomus tumor.^{2,3}

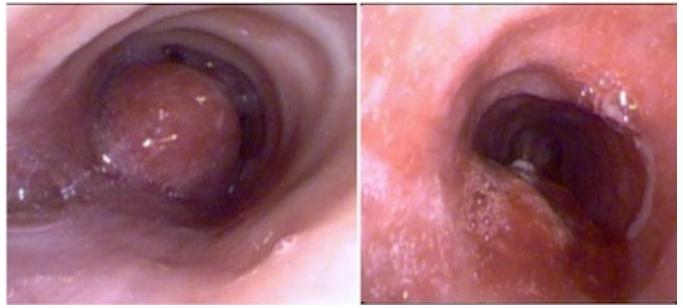
Glomus tumors of the trachea are exceedingly rare, with just over 40 cases described in the literature, and only six reports of glomangioma subtype arising from the trachea.⁴ Glomus tumors tend to occur predominantly in men (3:1 ratio) and arise from the posterior membranous wall of the trachea. They usually present with dyspnea, hemoptysis and less frequently, signs of airway obstruction or stridor.³

Very rarely glomus tumors can be malignant – of the reported cases, there have only been 2 malignant glomus tumors of the trachea.⁴ In 2001, Folpoe et al⁵ analyzed 52 cases of glomus tumors and proposed a set of criteria for malignant glomus tumors: Tumors with a deep location and a size greater than 2 cm, or atypical mitotic figures, or moderate to high nuclear grade and 5 or more mitotic figures/50 HPF.

Due to the risk of recurrence and malignancy, the definitive management for glomus tumors arising in the trachea is usually surgical via a (partial) sternotomy approach with segmental tracheal resection and end-to-end anastomosis. However this procedure carries a significant risk of morbidity including injury to surrounding structures such as the recurrent laryngeal nerve, poor wound healing, infections, perioperative cardiac and pulmonary complications,³ and risk of death. For benign glomus tumors such as the glomangioma seen in this case with no extratracheal extension, the alternative strategy of initial bronchoscopic debulking followed by subsequent definitive

tracheal resection once the patient is optimized to better tolerate surgery.

Tracheal resection is curative provided negative margins are achieved. In a benign tumor such as glomus tumors not meeting criteria for malignancy, local control of the tumor burden and symptoms via bronchoscopic interventions is a reasonable bridge until the patient is ready for surgery.



Central Picture. Glomangioma pre and post bronchoscopy with argon laser, debridement & snare electrocautery

Acknowledgements: Guarantor statement and authors' contributions

C. Chima-Melton takes responsibility for the content of the manuscript, including the case compilation, description and literature review. Luis M. Moreta-Sainz, M.D. provided mentorship during the management and writing of this case.

REFERENCES

1. **Gowan RT, Shamji FM, Perkins DG, Maziak DE.** Glomus tumor of the trachea. *Ann Thorac Surg.* 2001 Aug;72(2):598-600. PubMed PMID: 11515904.
2. **Shin DH, Park SS, Lee JH, Park MH, Lee JD.** Oncocytic glomus tumor of the trachea. *Chest.* 1990 Oct;98(4):1021-3. PubMed PMID: 2170078.
3. **Tan Y, Yang P, Deng X, Tang Y.** Glomangioma of the trachea: A case report and literature review. *Oncol Lett.* 2015 Mar;9(3):1273-1277. Epub 2015 Jan 13. PubMed PMID: 25663896; PubMed Central PMCID: PMC4314979.
4. **Venegas O, Newton A, Vergara N, Singhal S, Predina JD.** Tracheal Glomus Tumor: A Case Report and Review of the Literature. *Rare Tumors.* 2017 Mar 28;9(1):6848. doi: 10.4081/rt.2017.6848. eCollection 2017 Mar 24. PubMed PMID: 28458792; PubMed Central PMCID: PMC5379231.
5. **Folpe AL, Fanburg-Smith JC, Miettinen M, Weiss SW.** Atypical and malignant glomus tumors: analysis of 52 cases, with a proposal for the reclassification of glomus tumors. *Am J Surg Pathol.* 2001 Jan;25(1):1-12. PubMed PMID: 11145243.

Submitted March 15, 2018

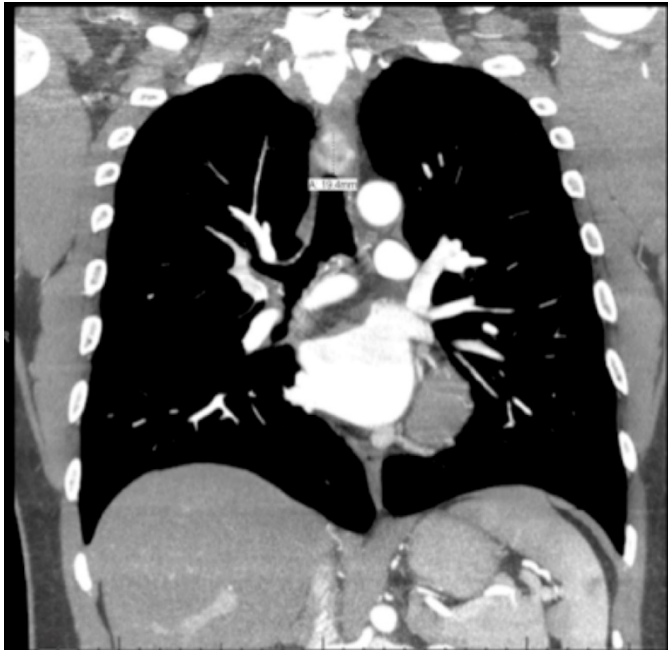


Figure 1. Computed Tomography appearance of tracheal mass

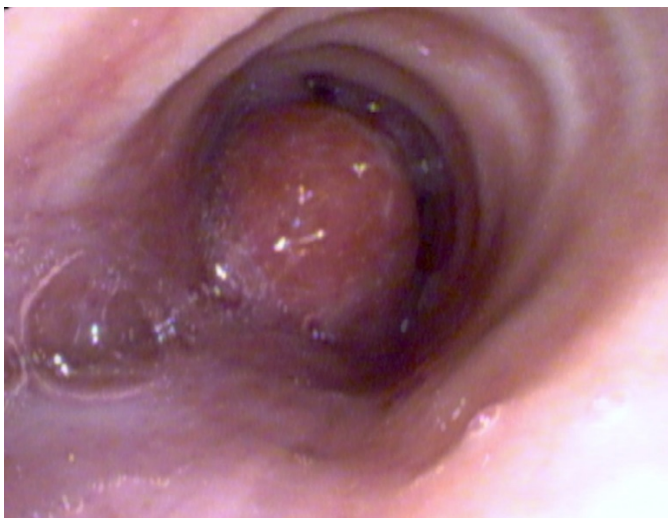

Figure 2. Bronchoscopic image of Glomus Tumor arising from posterior membranous tracheal wall.