

## CLINICAL VIGNETTE

---

# A Mind Gone Viral: An Unusual Case of Viral Encephalopathy

---

Christine Haynes, M.D., M.P.H., and Annie Zhang, M.D.

### **Introduction**

Acute retroviral syndrome affects over half of patients with new HIV infections and can present with a wide spectrum of symptoms. This heterogeneity presents a challenge to early diagnosis of HIV infection. Provider familiarity with these varied presentations, high clinical suspicion, and early appropriate testing are all critical to improving diagnostic accuracy. Early diagnosis is important both to optimize management of individual patients, especially given recent guideline recommendations for treatment of all patients with HIV regardless of CD4 count, as well as to minimize the public health risks of HIV transmission. We present one case in which HIV infection presented with acute encephalopathy, acute kidney injury, and metabolic derangements.

### **Case Discussion**

A 26-year-old previously healthy male was brought to the ER after a seizure in the setting of a recent febrile illness. Seven days prior to admission, he developed fevers, abdominal pain, nausea, vomiting, and diarrhea. The morning of admission he had a witnessed convulsive episode with loss of consciousness for two minutes and confusion for 15 minutes afterwards. His medical history revealed a diagnosis of G6PD deficiency, no medication use, a possible penicillin allergy, occasional tobacco use, and no recent travel or sexual partners.

On exam, he was afebrile with normal vital signs, in no acute distress, and oriented only to self. His mother noted unusual irritability. His sclerae were mildly icteric. His cardiopulmonary exam was unremarkable. He had mild hepatomegaly. His cranial nerves, strength, and sensation were intact. His gait was ataxic. His initial labs showed mild leukopenia, acute kidney injury, elevated aminotransaminases, hyperbilirubinemia, hyponatremia, metabolic acidosis, and a markedly elevated creatinine kinase. Urine toxicology was negative except for cannabinoids. A lumbar puncture and MRI brain were unremarkable. EEG demonstrated nonspecific frontal intermittent rhythmic delta activity.

He was empirically started on vancomycin, aztreonam, and acyclovir, which were subsequently discontinued when his CSF studies returned negative, as was a meningoencephalitis panel. After 48 hours of IV fluid resuscitation and observation, his

mental status normalized, as did his laboratory abnormalities. The working diagnosis was viral encephalitis of unclear etiology. However, after five days his HIV RNA PCR returned with 2.3 million copies, and he was diagnosed with acute HIV infection. He was discharged and initiated on ART therapy as an outpatient.

### **Discussion**

#### *Background and Epidemiology*

More than 1.2 million individuals in the U.S. are living with HIV, and 39,513 people were diagnosed with new HIV infection in 2015. Gay and bisexual men and African Americans are disproportionately affected by HIV. An estimated 13% of people with HIV have not been diagnosed, which poses a significant challenge to prevention of transmission and early treatment. However, the rate of new diagnoses declined by 19% from 2005 to 2014.<sup>1</sup>

#### *Pathophysiology*

HIV is most commonly transmitted via the anogenital mucosa, after which it infects dendritic cells, macrophages, and subsequently CD4+ lymphocytes. Infection can also occur through genital-oral sex, injection drug use, transfusion of blood products, and needle stick exposure. Disruptions in the mucosal membrane due to infection or inflammation increases the risk of transmission. Time from mucosal infection to initial viremia is estimated at 4 to 11 days in humans.<sup>2</sup> Acute viremia is followed by a rise in HIV RNA levels and drop in CD4+ lymphocytes. There may be considerable variability in incubation period before symptoms develop and time to peak viremia.<sup>2,3</sup> The highest frequency of signs and symptoms of acute retroviral syndrome has been observed immediately prior to peak viremia.<sup>4</sup> As viremia progresses, HIV-specific cellular immunity also develops. HIV-specific CD8+ cytotoxic T lymphocytes increase in number, plasma RNA falls logarithmically, and symptoms of acute retroviral syndrome resolve.

## *Clinical Manifestations*

Accurate estimates of the prevalence of acute retroviral syndrome among patients recently infected with HIV are difficult to obtain as many patients do not present to healthcare settings upon initial infection.<sup>5</sup> An estimated 40-90% will have some symptoms within two to four weeks of infection. Typical symptoms are nonspecific, including fever, fatigue, sore throat, rash, headache, lymphadenopathy, myalgias/arthralgias, mucocutaneous ulcers, and diarrhea. However, a number of atypical symptoms have been reported, ranging from neurologic sequelae (aseptic meningitis or encephalopathy) to pancreatitis, rhabdomyolysis, or vasculitis. Opportunistic infections can also develop during transient CD4 lymphopenia including candidiasis, pneumocystis jiroveci pneumonia, cytomegalovirus, and cryptococcus.<sup>6-9</sup>

## *Diagnosis and Testing*

The CDC recommends routine HIV testing at least once for all patients from ages 13-64 and for all pregnant women. This should be offered to patients regardless of sexual activity and risk factors, although in high-risk populations, more frequent testing is necessary. New CDC guidelines released in 2014 recommend the 4<sup>th</sup> generation combined antigen/antibody screening test. This immunoassay test detects both the p24 antigen (detectable from 15 to 45 days after infection) as well as HIV antibody levels (detectable starting at 25 days after infection), shortening the window period, the period after infection but before possible detection with a positive test by about 10 days.<sup>10</sup> These timelines are demonstrated in Figure 1. This recommendation was based partially on the results of the TESTAZ program in which 20% of patients who were newly diagnosed with HIV had a positive fourth generation test but negative third generation (antibody only) test.<sup>11</sup>

Additionally, HIV RNA begins to rise about 10 days after infection; as a result for patients who indicate that they may have had a recent HIV exposure, or when acute HIV infection is suspected, it is often appropriate to send the HIV RNA PCR as well. Note that this test should always be combined with an antibody test as it has not been FDA approved for the diagnosis of HIV, and low-level viral loads can be falsely positive.

Given the persistently high number of patients with HIV who are undiagnosed, there is a need for increased recognition of symptoms of acute HIV infection. A retrospective observational study found that only 5 of 19 patients with acute HIV infection were correctly diagnosed.<sup>12</sup> Another prospective trial of 290 patients with primary HIV infection found that acute HIV infection was initially suspected in only 112 (38%) of the patients. This may be partially because 25% had atypical symptoms. Those with atypical acute retroviral syndrome were more likely to be seen in the ER (vs. clinic, OR 2.7) and to be hospitalized (43% vs 11%, OR 4.4).<sup>13</sup> It is also important for providers to consider the HIV RNA PCR in patients with very recent exposures, in whom even the 4<sup>th</sup> generation test may not yet be positive, and to consider retesting patients who are initially negative but may have had an exposure within the last 10 days.<sup>10</sup>

## *Management/Treatment*

Treatment of acute retroviral syndrome is largely supportive and symptom-driven. Early diagnosis can help prevent the use of unnecessary treatments (such as antibiotics) and also leads to an opportunity for early HIV treatment.

There are many theoretical rationales for the introduction of ART during acute infection. Decreasing viral replication could help reduce the risk of viral transmission, reduce the severity and duration of illness of acute retroviral infection, and reduce the emergence of viral mutations. There is also the potential to preserve HIV-specific immune function, including the reservoir of CD4 cells.<sup>14</sup> Two studies found decreased viral load, increased CD4 count, and more specific CD8 response and differentiation with initiation of early ART, although these achievements declined with time after ART was stopped, indicating the importance of continuation of therapy and encouraging compliance.<sup>15,16</sup>

While it did not address acute HIV infection directly, the recently published START trial randomized patients with CD4 counts over 500 to immediately starting ART or to deferred initiation of ART until their CD4 count was under 350, and found a decrease in their primary end point (any serious AIDS-related event, serious non-AIDS-related event, or death from any cause) without an increased rate of adverse events, across all subpopulations.<sup>17</sup>

The other important component of management at this stage is the early connection to care, to establish a relationship with an HIV provider. It also involves extensive counseling, including about the need for close follow-up, medication adherence, and the risk of transmitting HIV, especially during acute HIV infection.

Diagnosis and treatment has a significant public health implication. Acute HIV infection represents a time of high infectivity; viral loads are usually 100,000 to >1 million. When patients are unaware of their HIV infection status, they may participate in risky behaviors without knowing they need to take precautions to help prevent the spread of infection. Additionally, many newly infected HIV patients are young and otherwise healthy with few healthcare exposures. If they do present to a healthcare setting with symptoms of acute retroviral syndrome, it provides a unique opportunity for testing and subsequent intervention. This reinforces the need to consider acute HIV infection in the differential for a wide variety of chief complaints, and to offer universal HIV testing for patients, even if they do not have symptoms consistent with acute HIV infection or risk factors for HIV transmission.

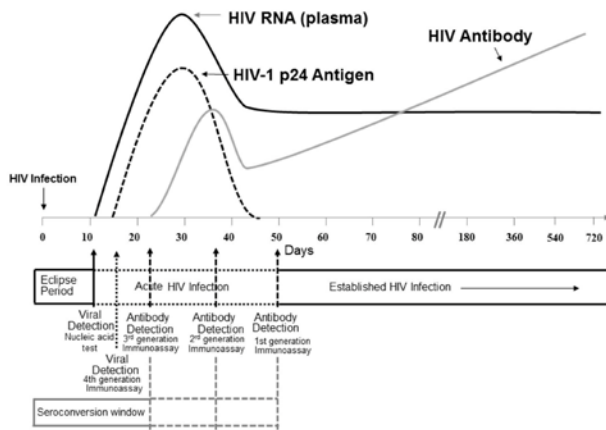
## *Conclusion*

Given the persistently high number of HIV positive patients who remain undiagnosed, there is a need for ongoing awareness of potential symptoms of acute HIV infection. This case demonstrated a particularly dramatic acute retroviral syndrome affecting multiple organ systems, including atypical features of encephalitis, hepatitis, rhabdomyolysis, and acute renal

insufficiency. It is essential for clinicians to recognize typical and atypical symptoms of acute retroviral syndrome to lead to improved testing and diagnostic accuracy and ultimately to help both reduce transmission and initiate prompt treatment of patients.

## Figures

**Figure 1.** Timeline of available HIV testing methods. Taken from CDC: Laboratory Testing for the Diagnosis of HIV Infection.<sup>10</sup>



## REFERENCES

1. **Center for Disease Control Statistics Center.** HIV in the United States: At a Glance. CDC, 2015.
2. **Kahn JO, Walker BD.** Acute human immunodeficiency virus type 1 infection. *N Engl J Med.* 1998 Jul 2;339(1):33-9. Review. PubMed PMID: 9647878.
3. **Ridzon R, Gallagher K, Ciesielski C, Ginsberg MB, Robertson BJ, Luo CC, DeMaria A Jr.** Simultaneous transmission of human immunodeficiency virus and hepatitis C virus from a needle-stick injury. *N Engl J Med.* 1997 Mar 27;336(13):919-22. PubMed PMID: 9070472.
4. **Robb ML, Eller LA, Kibuuka H, Rono K, Maganga L, Nitayaphan S, Kroon E, Sawe FK, Sinei S, Sriplienchan S, Jagodzinski LL, Malia J, Manak M, de Souza MS, Tovanabutra S, Sanders-Buell E, Rolland M, Dorsey-Spitz J, Eller MA, Milazzo M, Li Q, Lewandowski A, Wu H, Swann E, O'Connell RJ, Peel S, Dawson P, Kim JH, Michael NL; RV 217 Study Team.** Prospective Study of Acute HIV-1 Infection in Adults in East Africa and Thailand. *N Engl J Med.* 2016 Jun 2;374(22):2120-30. doi: 10.1056/NEJMoa1508952. Epub 2016 May 18. PubMed PMID: 27192360; PubMed Central PMCID: PMC5111628.
5. **Daar ES, Pilcher CD, Hecht FM.** Clinical presentation and diagnosis of primary HIV-1 infection. *Curr Opin HIV AIDS.* 2008 Jan;3(1):10-5. doi:10.1097/COH.0b013e3282f2e295. PubMed PMID: 19372938.
6. **Bitar A, Altaf M, Sferra TJ.** Acute pancreatitis: Manifestation of acute HIV infection in an adolescent. *Am*

*J Case Rep.* 2012;13:17-8. doi: 10.12659/AJCR.882323. Epub 2012 Jan 20. PubMed PMID: 23569476; PubMed Central PMCID: PMC3616115.

7. **Ferrada MA, Xie Y, Nuermberger E.** Primary HIV infection presenting as limbic encephalitis and rhabdomyolysis. *Int J STD AIDS.* 2015 Oct;26(11):835-6. doi: 10.1177/0956462414560777. Epub 2014 Nov 20. PubMed PMID: 25414090.
8. **Nzwalo H, Añón RP, Àguas MJ.** Acute encephalitis as initial presentation of primary HIV infection. *BMJ Case Rep.* 2012 Jul 3;2012. pii: bcr0320125970. doi:10.1136/bcr.03.2012.5970. PubMed PMID: 22761210; PubMed Central PMCID: PMC3391397.
9. **Silva Mde O, Bastos M, Netto EM, Gouvea NA, Torres AJ, Kallas E, Watkins DI, Altfeld M, Brites C.** Acute HIV infection with rapid progression to AIDS. *Braz J Infect Dis.* 2010 May-Jun;14(3):291-3. PubMed PMID: 20835515.
10. **Branson BM, Owen SM, Wesolowski LG, Bennett B, Werner BG, Wroblewski KE, Pentella MA.** Laboratory Testing for the Diagnosis of HIV Infection: Updated Recommendations. *Center for Disease Control and Prevention and Association of Public Health Laboratories.* 2014 Jun 27.
11. **Geren KI, Lovecchio F, Knight J, Fromm R, Moore E, Tomlinson C, Valdez A, Hobohm D, Stapczynski JS.** Identification of acute HIV infection using fourth-generation testing in an opt-out emergency department screening program. *Ann Emerg Med.* 2014 Nov;64(5):537-46. doi: 10.1016/j.annemergmed.2014.05.021. Epub 2014 Jun 23. PubMed PMID: 24970245.
12. **Schacker T, Collier AC, Hughes J, Shea T, Corey L.** Clinical and epidemiologic features of primary HIV infection. *Ann Intern Med.* 1996 Aug 15;125(4):257-64. Erratum in: *Ann Intern Med* 1997 Jan 15;126(2):174. PubMed PMID: 8678387.
13. **Braun DL, Kouyos RD, Balmer B, Grube C, Weber R, Günthard HF.** Frequency and Spectrum of Unexpected Clinical Manifestations of Primary HIV-1 Infection. *Clin Infect Dis.* 2015 Sep 15;61(6):1013-21. doi: 10.1093/cid/civ398. Epub 2015 May 19. PubMed PMID: 25991469.
14. **O'Brien M, Markowitz M.** Should we treat acute HIV infection? *Curr HIV/AIDS Rep.* 2012 Jun;9(2):101-10. doi: 10.1007/s11904-012-0113-0. Review. PubMed PMID:22415472; PubMed Central PMCID: PMC3718035.
15. **Streeck H, Jessen H, Alter G, Teigen N, Waring MT, Jessen A, Stahmer I, van Lunzen J, Lichtenfeld M, Gao X, Allen TM, Carrington M, Walker BD, Rockstroh JK, Altfeld M.** Immunological and virological impact of highly active antiretroviral therapy initiated during acute HIV-1 infection. *J Infect Dis.* 2006 Sep 15;194(6):734-9. Epub 2006 Aug 15. PubMed PMID: 16941338.
16. **Hecht FM, Wang L, Collier A, Little S, Markowitz M, Margolick J, Kilby JM, Daar E, Conway B, Holte S; AIEDRP Network.** A multicenter observational study of the potential benefits of initiating combination antiretroviral therapy during acute HIV infection. *J Infect*

*Dis.* 2006 Sep 15;194(6):725-33. Epub 2006 Aug 15.  
PubMed PMID: 16941337.

17. **INSIGHT START Study Group, Lundgren JD, Babiker AG, Gordin F, Emery S, Grund B, Sharma S, Avihingsanon A, Cooper DA, Fätkenheuer G, Libre JM, Molina JM, Munderi P, Schechter M, Wood R, Klingman KL, Collins S, Lane HC, Phillips AN, Neaton JD.** Initiation of Antiretroviral Therapy in Early Asymptomatic HIV Infection. *N Engl J Med.* 2015 Aug 27;373(9):795-807. doi: 10.1056/NEJMoa1506816. Epub 2015 Jul 20. PubMed PMID: 26192873; PubMed Central PMCID: PMC4569751.

*Submitted July 27, 2017*