

## CLINICAL VIGNETTE

# May-Thurner syndrome: Iliac Vein Compression Syndrome

Jeffrey S. Goldsmith M.D.

### *Case Report*

A previously healthy 30-year-old female presented to the emergency room with two days of left groin pain and increasing swelling of the lower leg. She became acutely dyspneic with minimal exertion, and lightheaded with substernal chest pain. A pulmonary CT angiogram revealed multiple pulmonary thromboemboli within the bilateral intermediate and multilobar segmental and subsegmental arteries. The scan did not extend to the pelvis. Venous duplex ultrasound was free of deep venous thrombosis in the bilateral lower extremities, however decreased blood flow velocity in the left common femoral vein was noted, suggesting a more proximal venous system obstruction. The patient received treatment initially with unfractionated heparin, and then transitioned to Enoxaparin injections. Prior to initiating Warfarin, an extensive hypercoagulable workup was initiated including factor V Leiden mutation analysis, prothrombin 20210A variant mutation analysis, protein C activity, protein S antigen, antithrombin III level, homocystine level, antiphospholipid antibodies, ANA, diluted Russell's viper venom time.

The patient's symptoms of groin pain and dyspnea promptly improved within 3 days of treatment. She was ambulatory with normal hemodynamics and felt to be stable for outpatient management on Enoxaparin while transitioning to Warfarin. By the seventh day of Enoxaparin, her INR was therapeutic at 2.7 seconds and the injections were discontinued.

Approximately one week after discontinuing the Enoxaparin, the patient developed recurrent symptoms of left sided groin pain. Her INR was 3.0 seconds. A repeat duplex ultrasound of the lower extremity demonstrated acute deep venous thrombosis in the left proximal common femoral vein not previously noted. Enoxiparin was resumed and Warfarin was discontinued.

The patient's hypercoagulable work-up was entirely normal. Her only medication was an

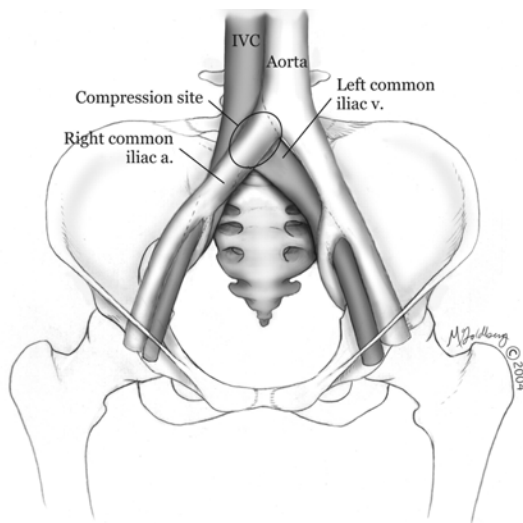
oral contraceptive, and she had been taking this uneventfully for 9 years. This was discontinued at the time of her initial admission. She had no family history of venous thromboembolic disease. She had one uneventful pregnancy four years earlier with vaginal delivery, and one remote first trimester miscarriage. Prior to her initial presentation, she had no significant complaints, recent illness, weight changes or prolonged travel.

An MR venogram was obtained to assess the iliac venous system. The right common iliac artery was noted to cross the left common iliac vein. At the point of crossing, the common iliac vein appeared occluded, but without visible intra-luminal thrombus. There was however thrombus noted in the left external iliac and left common femoral vein. These findings were consistent with May-Thurner syndrome. Ultimately, thrombolysis of the areas of clot was performed. Subsequently, the region of stenosis in the left common iliac vein was successfully angioplastied, and then an appropriate stent was placed. The patient was maintained on Enoxaparin for an additional month and gradually transitioned back to Warfarin. At the 6-month follow-up, the patient was found to be symptom free. Her stent remained patent, and Warfarin therapy was continued for approximately a year. At that point repeat ultrasonography showed no evidence of deep venous thrombosis, and anticoagulation was discontinued. She remains off oral contraceptives and symptom free.

### *Discussion*

Symptomatic compression of the left common iliac vein by the right common iliac artery, leading to subsequent deep venous thrombosis was first described by May and Thurner in 22% of patients in an autopsy series<sup>1</sup>. They hypothesized that repetitive compression of the

left iliac vein from pulsations of the overlying right common iliac artery had lead to scarring and ultimately stenosis of the left iliac vein.



2

In up to 50% of patients with left iliac vein thrombosis, this iliac vein compression syndrome has been documented<sup>3</sup>. Compression of up to 50% of the vessel has been demonstrated in a quarter of asymptomatic patients studied without incidence of thrombosis. The compression of the left iliac vein itself may be an anatomic variant, and alone is not necessarily a pathological condition. The proportion of those who will advance to develop thrombosis remains unclear. In the relatively small studies, the incidence appears to be higher in women compared with men, and peak age of onset of thrombosis occurs between the third to fifth decades of life<sup>4-6</sup>.

In the patient described above, venous duplex ultrasonography failed to demonstrate an acute thrombosis. While decreased velocity of the common femoral vein was noted on this patient's initial study, adequate visualization of the iliac vessels with this technique is very limited<sup>7</sup>. When the patient developed recurrent deep venous thrombosis within a week of bridging Warfarin therapy, MR venography was obtained to assess for iliac vein compression syndrome. MR venography has similar sensitivity and specificity to invasive venography<sup>8</sup>. Clot burden

was noted in the adjacent external iliac vein, along with stenosis of the common iliac vein. As a result, thrombolysis and subsequent angioplasty and stent support of the compressed left common iliac vein was performed. This approach is a viable means of preventing recurrent thrombosis and limb threatening complications from thromboses<sup>9-10</sup>. While studies published are observational only, they demonstrate that thrombolysis of early clot burden can preserve valvular function and reduce risk of venous insufficiency<sup>11</sup>. While long term outcomes of venous angioplasty for patients with May-Thurner syndrome are lacking, reports of low complication rates, as well as patency rates of 79-100% have been noted up to three years after angioplasty procedures are performed<sup>9-10</sup>.

Iliac vein compression syndrome, or May-Thurner syndrome, should be considered if no other hypercoagulable state or a left sided recurrent deep venous thrombosis is noted. It is important to be aware of the limitations of routine lower extremity duplex ultrasonography in describing pelvic vein thrombosis, and consider alternate imaging techniques to help clarify anatomy of concern more proximal to the thigh deep venous system.

## REFERENCES

1. **May R, Thurner J.** The cause of the predominantly sinistral occurrence of thrombosis of the pelvic veins. *Angiology*. 1957 Oct;8(5):419-27. PubMed PMID:13478912.
2. **Grunwald MR, Goldberg MJ, Hofmann LV.** Endovascular management of May-Thurner syndrome. *AJR Am J Roentgenol*. 2004 Nov;183(5):1523-4. PubMed PMID: 15505333.
3. **Mickley V, Schwagierek R, Rilinger N, Görich J, Sunder-Plassmann L.** Left iliac venous thrombosis caused by venous spur: treatment with thrombectomy and stent implantation. *J Vasc Surg*. 1998 Sep;28(3):492-7. PubMed PMID: 9737459.
4. **Cockett FB, Thomas ML.** The iliac compression syndrome. *Br J Surg*. 1965 Oct;52(10):816-21. PubMed PMID: 5828716.
5. **Kibbe MR, Ujiki M, Goodwin AL, Eskandari M, Yao J, Matsumura J.** Iliac vein compression in an asymptomatic patient population. *J Vasc Surg*. 2004 May;39(5):937-43. PubMed PMID: 15111841.
6. **Fazel R, Froehlich JB, Williams DM, Saint S, Nallamotheu BK.** Clinical problem-solving. A sinister development--a 35-year-old woman presented to the emergency department with a 2-day history of progressive swelling and pain in her left leg, without antecedent trauma. *N Engl J Med*. 2007 Jul 5;357(1):53-9. PubMed PMID: 17611208.
7. **Messina LM, Sarpa MS, Smith MA, Greenfield LJ.** Clinical significance of routine imaging of iliac and calf veins by color flow duplex scanning in

- patients suspected of having acute lower extremity deep venous thrombosis. *Surgery*. 1993 Nov;114(5):921-7. PubMed PMID: 8236016.
8. **Evans AJ, Sostman HD, Knelson MH, Spritzer CE, Newman GE, Paine SS, Beam CA.** 1992 ARRS Executive Council Award. Detection of deep venous thrombosis: prospective comparison of MR imaging with contrast venography. *AJR Am J Roentgenol*. 1993 Jul;161(1):131-9. PubMed PMID: 8517292.
  9. **O'Sullivan GJ, Semba CP, Bittner CA, Kee ST, Razavi MK, Sze DY, Dake MD.** Endovascular management of iliac vein compression (May-Thurner) syndrome. *J Vasc Interv Radiol*. 2000 Jul-Aug;11(7):823-36. PubMed PMID: 10928517.
  10. **Patel NH, Stookey KR, Ketcham DB, Cragg AH.** Endovascular management of acute extensive iliofemoral deep venous thrombosis caused by May-Thurner syndrome. *J Vasc Interv Radiol*. 2000 Nov-Dec;11(10):1297-302. PubMed PMID: 11099239.
  11. **Augustinos P, Ouriel K.** Invasive approaches to treatment of venous thromboembolism. *Circulation*. 2004 Aug 31;110(9 Suppl 1):I27-34. Review. PubMed PMID: 15339878.

Submitted on February 17, 2012