

CLINICAL VIGNETTE

Dilemma of Right Atrial Thrombi, to Dissolve or to Extract

Lawrence Lazar, M.D., Ravi Dave, M.D., Ramin Tabibiazar, M.D.

Case Report

A 69-year-old male with hypertension and dyslipidemia presented to the ER with syncope and dyspnea. The patient experienced 2 syncopal episodes during exertion. He also reported 3-weeks of progressive dyspnea on exertion with no improvement with antibiotics, steroids, or inhalers. He reported multiple long flights in the past several weeks. In the ER, his vital signs included BP of 93/65, pulse of 111 bpm, respiratory rate of 18 cycles/min, with 99% oxygen saturation on room air. EKG showed right axis deviation and non-specific ST and T wave changes. His laboratory data were notable for creatinine 1.6, elevated BNP of 607, and troponin of 0.66.

The patient underwent urgent echocardiogram, which revealed a borderline hypokinetic left ventricle (LV) with EF 50% and a moderately dilated and hypokinetic right ventricle with mildly elevated pulmonary artery pressures. In addition, there was a large mobile echogenic mass in the right atrium measuring 4 cm x 1.5 cm, protruding into the right ventricle, compatible with right heart thrombus (Figure 1). The patient was started immediately on heparin and underwent urgent radiographic studies including CT angiography of his chest and venous Doppler of his lower extremities. The CT angiography showed multiple filling defects in bilateral pulmonary arteries consistent with acute pulmonary thromboemboli (Figure 1). Venous Doppler showed acute DVT in the right popliteal, posterior tibial and peroneal veins (Figure 1).

The patient was admitted to the intensive care unit, and an urgent CT surgery consultation was obtained. Surgical intervention was considered, but deferred due to high operative mortality risk. The patient underwent placement of an IVC filter via femoral approach and catheter-directed thrombolysis. He tolerated the procedure well without complications, and he was discharged on oral anticoagulation. Serial echocardiograms documented eventual resolution of right heart

thrombi and normalization of pulmonary artery pressures as well as LV and RV function.

Discussion

Right atrial thrombi have been described in patients with atrial fibrillation/flutter, central venous catheters, or pacemaker leads¹. In-situ right atrial thrombi are usually immobile, attached to the atrial wall with occasional calcification. Secondary right atrial thrombi are often mobile as they have propagated from the peripheral veins, and are in transit to embolize into the pulmonary arteries. Thus, these mobile right heart thrombi have often been referred to as “emboli in transit”². Mobile right atrial thrombi have been described as spherical, coiled, grapelike, ovoid, worm-like or serpiginous masses moving within the right atrium, and if large, they may prolapse through the tricuspid valve and into the right ventricle¹. Often, these masses appear free-floating with no attachment site.

While nearly all of the detected cases of mobile right heart thrombi are diagnosed when echocardiography is performed in patients with suspected PE or proven PE, the true incidence of mobile right heart thrombi may be difficult to ascertain². In patients with PE, it is not uncommon to detect thrombi in the right atria during echocardiography, and in unselected patients with PE, about 4% of patients have right atrial thrombi³. When compared to trans-esophageal echocardiography, transthoracic echocardiography may have lower sensitivity to detect right heart thrombi and may underestimate the clot burden². As a result, the incidence of mobile right heart thrombi may be under-estimated due to the preference of using transthoracic rather than transesophageal echo-cardiography in clinical practice. In an autopsy study which included 23,796 subjects and represented 84% of all in-hospital deaths during a 13-year interval, right intracardiac thrombi were seen in nearly 7% of cases with PE⁴. However, the postmortem incidence may be lower than the actual antemortem incidence since embolization of right heart thrombi into the pulmonary arteries may have caused death^{2,4}.

The detection of mobile right heart thrombi has diagnostic and therapeutic implications. The detection of right heart thrombi may support the diagnosis of PE and may expedite therapy.

Furthermore, the detection of right heart thrombi on echo may prevent the risks associated with contrast. Transjugular placement of inferior vena cava filter may be avoided in order to not dislodge the right atrial thrombi², and IVC filters may be placed via femoral vein.

Patients with PE and right atrial thrombi have a higher early mortality rate, particularly when the thrombi are mobile^{2,5}. Patients with PE and right atrial thrombi are more likely to have hemodynamic compromise, hypotension, and tachycardia^{3,6,7}. The presence of mobile right atrial thrombi should be considered a potentially life-threatening situation with high risk of recurrent PE⁵. If patients remain untreated, the death rate has been reported at 80-100% as the free-floating thrombi in the right heart embolize into an already severely compromised pulmonary circulation. Thus, it is imperative to start therapy immediately in order to improve survival.

Although the presence of right heart thrombi in patients with PE is associated with increased mortality, little is known about optimal management of this difficult clinical situation. The treatment of choice remains controversial with limited data to compare the various options. In a meta-analysis that included 177 cases, the overall mortality rate was 27%². The mortality rate associated with no therapy, anticoagulation therapy, embolectomy, and thrombolysis were 100%, 29%, 24%, and 11%, respectively². These findings suggest that anticoagulation by itself appears insufficient to treat patients with mobile right heart thrombi. This study further suggests that thrombolysis is the preferred option in the absence of contraindications over embolectomy². However, the results of this study need to be interpreted cautiously given the various limitations of a meta-analysis. Therefore, there is a need for a well-designed prospective, randomized trial in order to determine the optimal treatment for patients with PE and right heart thrombi.

Thrombolytic therapy can be administered quickly. Systemic thrombolytics may dissolve thrombi in various areas including pulmonary arteries, intracardiac chambers, and venous circulation. Three lytic drugs have been approved by the FDA for severe pulmonary embolism, including urokinase, streptokinase, and rtPA⁵. Thrombolytic agents may accelerate thrombus lysis and pulmonary reperfusion, reduce pulmonary hypertension, as well as improve right ventricular function and overall cardiac function^{5,8}. With systemic thrombolysis, there is a theoretical concern for disrupting the attachment site of the thrombi with dislodgment into pulmonary arteries.

Catheter-directed thrombolysis has been described as a potential option for treatment of right atrial thrombi and PE, but data are scarce⁹. Thrombolytic therapy is associated with an increased risk of bleeding, including intracranial hemorrhage and retroperitoneal hemorrhage^{2,10}.

Embolectomy is typically limited to large medical centers since it requires an experienced surgeon and cardiopulmonary bypass. When there are contraindications to thrombolysis, embolectomy may become the preferred therapeutic option. A potential advantage of surgical approach is the ability to repair a patent foramen ovale, and reduce the risk of subsequent paradoxical embolism and stroke². The potential disadvantages with surgical embolectomy include an inherent delay in operation of at least hours, general anesthesia, cardiopulmonary bypass, and inability to remove thromboemboli beyond the central pulmonary arteries. Also, the availability of an experienced surgical staff may limit surgical options when considering therapy for patients with mobile right heart thrombi. Percutaneous approach with catheter-directed retrieval of clots has been promising, but data regarding catheter embolectomy is limited^{2,11,12}.

In conclusion, the detection of right heart thromboemboli during echocardiography may have diagnostic and therapeutic implications. The presence of mobile right atrial thrombi in patients with PE portends poor prognosis with cardiopulmonary collapse due to PE. Therefore, treatment should be started immediately as any delay in administering therapy may be lethal. The optimal therapy remains controversial given absence of randomized trials. Yet in certain cases, the different approaches may prove to be complementary and not necessarily exclusive. While thrombolysis and embolectomy appear effective, anticoagulation alone appears insufficient.

REFERENCES:

1. **Panduranga P, Mukhaini M, Saleem M, Al-Delamie T, Zachariah S, Al-Taie S.** Mobile right heart thrombus with pulmonary embolism in a patient with polycythemia rubra vera and splanchnic vein thrombosis. *Heart Views*. 2010 Mar;11(1):16-20. PubMed PMID: 21042459; PubMed Central PMCID: PMC2964707.
2. **Rose PS, Punjabi NM, Pearse DB.** Treatment of right heart thromboemboli. *Chest*. 2002 Mar;121(3):806-14. PubMed PMID: 11888964.
3. **Torbicki A, Galié N, Covezzoli A, Rossi E, De Rosa M, Goldhaber SZ;** ICOPER Study Group. Right heart thrombi in pulmonary embolism: results from the International Cooperative Pulmonary Embolism Registry. *J Am Coll Cardiol*. 2003 Jun 18;41(12):2245-51. PubMed PMID: 12821255.

4. **Ogren M, Bergqvist D, Eriksson H, Lindblad B, Sternby NH.** Prevalence and risk of pulmonary embolism in patients with intracardiac thrombosis: a population-based study of 23 796 consecutive autopsies. *Eur Heart J.* 2005 Jun;26(11):1108-14. Epub 2005 Feb 4. PubMed PMID: 15695529.
5. **Chartier L, Béra J, Delomez M, Asseman P, Beregi JP, Bauchart JJ, Warembourg H, Théry C.** Free-floating thrombi in the right heart: diagnosis, management, and prognostic indexes in 38 consecutive patients. *Circulation.* 1999 Jun 1;99(21):2779-83. PubMed PMID: 10351972.
6. **Torbicki A, Perrier A, Konstantinides S, Agnelli G, Galìè N, Pruszczyk P, Bengel F, Brady AJ, Ferreira D, Janssens U, Klepetko W, Mayer E, Remy-Jardin M, Bassand JP;** ESC Committee for Practice Guidelines (CPG). Guidelines on the diagnosis and management of acute pulmonary embolism: the Task Force for the Diagnosis and Management of Acute Pulmonary Embolism of the European Society of Cardiology (ESC). *Eur Heart J.* 2008 Sep;29(18):2276-315. Epub 2008 Aug 30. PubMed PMID: 18757870.
7. **Ferrari E, Benhamou M, Berthier F, Baudouy M.** Mobile thrombi of the right heart in pulmonary embolism: delayed disappearance after thrombolytic treatment. *Chest.* 2005 Mar;127(3):1051-3. PubMed PMID: 15764793.
8. **Goldhaber SZ.** Thrombolysis for pulmonary embolism. *Prog Cardiovasc Dis.* 1991 Sep-Oct;34(2):113-34. Review. PubMed PMID: 1909807.
9. **Maron BA, Goldhaber SZ, Sturzu AC, Rhee DK, Ali BS, Shah PB, Kirshenbaum JM.** Catheter-directed thrombolysis for giant right atrial thrombus. *Circ Cardiovasc Imaging.* 2010 Jan;3(1):126-7. PubMed PMID: 20086226.
10. **Konstantinides S, Geibel A, Olschewski M, Heinrich F, Grosser K, Rauber K, Iversen S, Redecker M, Kienast J, Just H, Kasper W.** Association between thrombolytic treatment and the prognosis of hemodynamically stable patients with major pulmonary embolism: results of a multicenter registry. *Circulation.* 1997 Aug 5;96(3):882-8. PubMed PMID: 9264496.
11. **Davies RP, Harding J, Hassam R.** Percutaneous retrieval of a right atrioventricular embolus. *Cardiovasc Intervent Radiol.* 1998 Sep-Oct;21(5):433-5. PubMed PMID: 9853154.
12. **Beregi JP, Aumégeat V, Loubeyre C, Couillet JM, Asseman P, Debacker-Steckelorum C, Bauchart JJ, Liu PC, Théry C.** Right atrial thrombi: percutaneous mechanical thrombectomy. *Cardiovasc Intervent Radiol.* 1997 Mar-Apr;20(2):142-5. PubMed PMID: 9030507.

Figure Legend

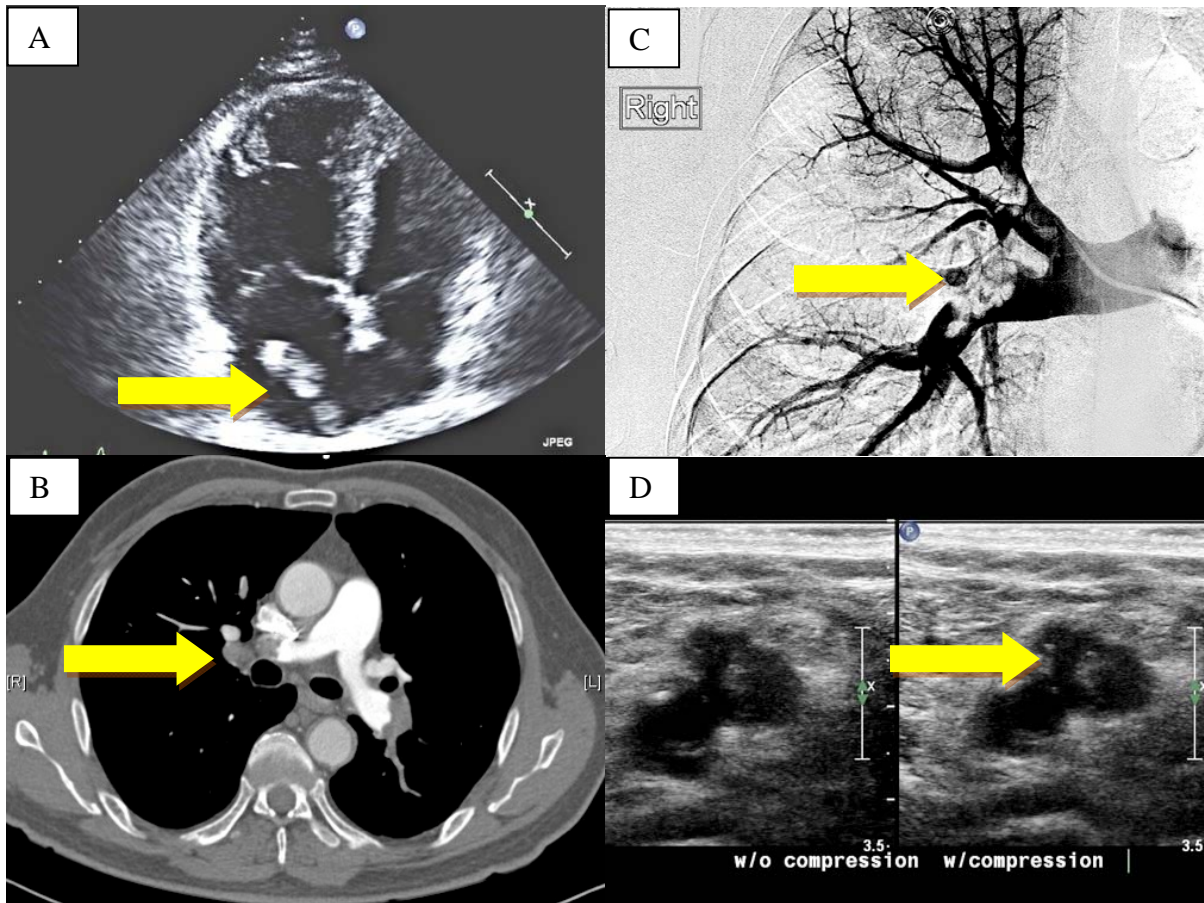


Figure 1:

A) A large right atrial thrombus seen during transthoracic echocardiogram. B) CT angiography showing extensive pulmonary embolism. C) Pulmonary artery angiography demonstrating large clots in the right pulmonary artery. D) Lower extremity compression ultrasound demonstrating non-compressible right popliteal vein.