

CLINICAL VIGNETTE

The Diagnostic Challenges of Differentiating TTP-HUS and HELLP Syndrome in an Anuric Post-Partum Patient

Sungwon Rachel Kyung, M.D., and Jeffrey Miller, M.D.

Case

A 37-year-old female with no significant medical history was diagnosed with severe pre-eclampsia during a pre-natal obstetric clinic visit with notable hypertension and proteinuria. The patient was at 37 weeks of gestation with twins.

The patient was admitted and subsequently underwent emergent Cesarean section for fetal bradycardia. Operative course was complicated by post-partum hemorrhage with a 1.4 liter estimated blood loss, and patient underwent blood transfusions and fluid resuscitation with an appropriate response.

On post-partum day 1, the patient was noted to be newly anemic and thrombocytopenic and received further transfusions and fluids for her anemia and hypotension. However, she also developed anuric acute kidney injury unresponsive to intravenous diuretics.

The patient's laboratory data were notable for a mild transaminitis two times the upper limit of normal, as well as a peripheral smear with evidence of schistocytes and a lactate dehydrogenase level >1000 IU/L. She subsequently developed respiratory compromise in the setting of volume overload and was transferred to the intensive care unit for respiratory management and emergent hemodialysis (Figure 1).

The differential diagnosis for this patient's microangiopathic hemolytic anemia and thrombocytopenia at this time included HELLP syndrome (in the setting of the temporal relationship to patient's pre-eclampsia and presence of transaminitis) as well as TTP-HUS (given the rapid onset of her anuria and a highly elevated LDH, as well as active urinary sediment consistent with a thrombotic microangiopathy).

Upon discussion amongst the hematology, renal, obstetrics, and critical care teams, the patient was planned for plasma exchange following completion of her hemodialysis after her fluid status was stabilized. The patient also received high-dose corticosteroid therapy and remained afebrile without any neurologic manifestations.

Ultimately, the patient was noted to have a low-grade DIC with coagulopathy and deemed to likely have HELLP syndrome, as DIC is often seen in HELLP syndrome but not observed in TTP-HUS. The patient's laboratory values gradually improved without the need for plasmapheresis and patient's renal function

recovered after several weeks of dialysis. The patient's ADAMTS13 level eventually resulted with a value at the lower limit of normal.

Discussion

Thrombotic microangiopathy (TMA) describes a spectrum of disorders characterized by microangiopathic hemolytic anemia (MAHA), thrombocytopenia, and microvascular thrombi resulting in end-organ damage.

Among primary TMAs, thrombotic thrombocytopenic purpura – hemolytic uremic syndrome (TTP-HUS) is associated with a deficiency of ADAMTS13, an enzyme that cleaves large multimers of von Willebrand Factor (vWF).^{1,2} This deficiency is often acquired due to development of an autoantibody against ADAMTS13 or in rare cases can be congenital from a mutation in the ADAMTS13 gene.³

The deficiency of ADAMTS13 results in circulating large vWF multimers that cause platelet adhesiveness, impair fibrinolytic activity, lead to platelet aggregation with thrombocytopenia, and simultaneously result in a pro-thrombotic state.⁴

TTP-HUS has been classically described by a pentad of thrombocytopenia, MAHA, neurologic symptoms, fever, and renal failure. Mortality rate without treatment can be up to 90%.³

TTP-HUS cases are rare but have been well-documented in pregnant or post-partum patients as pregnancy can precipitate a decrease in ADAMTS13 activity.⁵ The estimated incidence of TTP-HUS in pregnancies has been reported at 1 in 100,000.⁶

HELLP (hemolysis, elevated liver enzymes, low platelets) syndrome is thought to be a severe manifestation of pre-eclampsia and also includes MAHA. Incidence has been noted in 0.01-0.6% of pregnancies overall, and it has been documented in 5-10% of women with preeclampsia.⁶ The mortality rate of HELLP syndrome without treatment has been reported to be up to 25%.⁷ MAHA is the unifying presentation between these two diagnoses.

Because of the similarities of the clinical manifestations between TTP-HUS and HELLP syndrome, the diagnosis can often be challenging. However, management of the two syndromes differs. TTP-HUS requires prompt initiation of

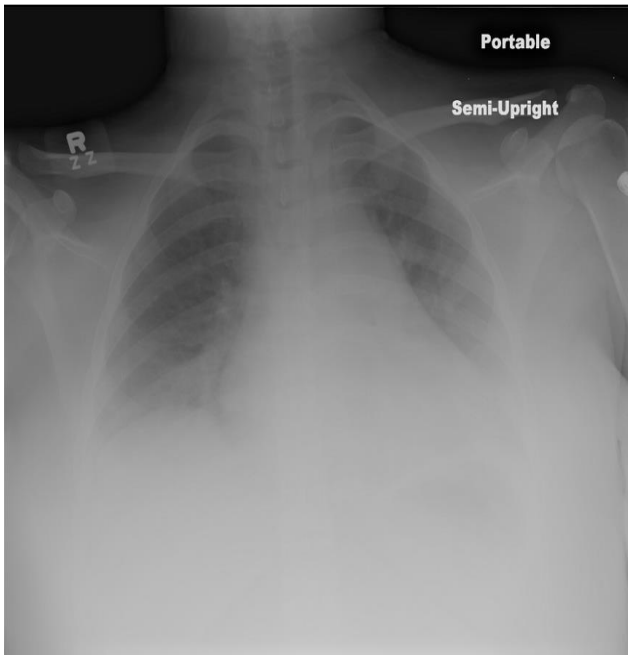
plasmapheresis with steroids in the acute setting and is followed by immunosuppressive agents while the treatment of HELLP syndrome is steroids, anti-hypertensives, and emergent delivery of the baby.^{3,7}

The decision to treat for TTP-HUS is usually made on a high index of clinical suspicion, as ADAMTS13 levels are generally not available at the time of diagnosis. In our case, the patient's acute renal failure, as well as the highly elevated LDH levels, made differentiating HELLP syndrome from TTP-HUS challenging, and it was the concomitant disseminated intravascular coagulation that helped eventually conclude HELLP syndrome as the ultimate diagnosis.

It is essential for clinicians to be able to identify these syndromes early and understand the necessity for prompt coordination of care with a multidisciplinary team given the similarities of both syndromes, the high mortality, and catastrophic effects associated with both TTP-HUS and HELLP syndrome without rapid initiation of therapy.

Figures

Figure 1. Chest X Ray of this patient demonstrating volume overload in the setting of new renal failure and anuria.



REFERENCES

1. **Furlan M, Robles R, Galbusera M, Remuzzi G, Kyrle PA, Brenner B, Krause M, Scharrer I, Aumann V, Mittler U, Solenthaler M, Lämmle B.** von Willebrand factor-cleaving protease in thrombotic thrombocytopenic purpura and the hemolytic-uremic syndrome. *N Engl J Med.* 1998 Nov 26;339(22):1578-84. PubMed PMID: 9828245.
2. **Tsai HM, Lian EC.** Antibodies to von Willebrand factor-cleaving protease in acute thrombotic thrombocytopenic purpura. *N Engl J Med.* 1998 Nov 26;339(22):1585-94. PubMed PMID: 9828246; PubMed Central PMCID: PMC3159001.

3. **Adamski J.** Thrombotic microangiopathy and indications for therapeutic plasma exchange. *Hematology Am Soc Hematol Educ Program.* 2014 Dec 5;2014(1):444-9. doi: 10.1182/asheducation-2014.1.444. Epub 2014 Nov 18. Review. PubMed PMID: 25696892.
4. **Fang CJ, Richards A, Liszewski MK, Kavanagh D, Atkinson JP.** Advances in understanding of pathogenesis of aHUS and HELLP. *Br J Haematol.* 2008 Nov;143(3):336-48. doi: 10.1111/j.1365-2141.2008.07324.x. Epub 2008 Aug 4. Review. PubMed PMID: 18691170.
5. **Sadler JE, Moake JL, Miyata T, George JN.** Recent advances in thrombotic thrombocytopenic purpura. *ASH Education Program Book.* 2004;2004(1):407-423.
6. **Berry EL, Iqbal SN.** HELLP Syndrome at 17 Weeks Gestation: A Rare and Catastrophic Phenomenon. *J Clin Gynecol Obstet.* 2014 Dec;3(4):147-150. PubMed PMID: 25806101; PubMed Central PMCID: PMC4369395.
7. **Martin JN Jr, Rose CH, Briery CM.** Understanding and managing HELLP syndrome: the integral role of aggressive glucocorticoids for mother and child. *Am J Obstet Gynecol.* 2006 Oct;195(4):914-34. Epub 2006 May 2. Review. PubMed PMID: 16631593.

Submitted July 12, 2016