

CLINICAL VIGNETTE

Transverse Leukonychia with Normocalcemic Hyperparathyroidism

Michael J Cunningham¹, M.S.; Ashley G Rubin², M.D.; and Lorraine C Young², M.D.

¹University of Vermont College of Medicine

²University of California, Los Angeles

Case

A 76-year-old male was referred to dermatology by his primary care physician for possible nail fungus. The patient had multiple horizontal white lines with convex curvature on his second through fifth fingernails bilaterally (Figures 1 and 2). The white discoloration did not fade when pressure was applied to the nail, and there were no transverse depressions corresponding to the white discolored areas. Skin and oral mucosa were clear, and there were no significant findings on the toenails. The patient denied any history of trauma to the nails or distal fingers and was retired from work. The patient noted that the chronology of his nail findings coincided with new parathyroid hormone elevations.

Over a decade ago, the patient had been diagnosed with primary hyperparathyroidism and subsequently underwent parathyroidectomy. Fifteen months before the presentation to our clinic, parathyroid hormone was elevated (at levels of 70-100 pg/ml, normal range of 10-55 pg/ml). During this time, the patient had serum calcium and phosphorus levels within their respective reference ranges but had slightly less vitamin D levels (25-hydroxyvitamin D at 20 ng/ml, normal range 30-74 ng/ml). These low vitamin D levels may have exacerbated the hyperparathyroidism as described previously.^{1,2} His parathyroid levels remained elevated, but invasive treatments were deferred as the patient was not symptomatic. His electrolytes were within normal limits. He was followed closely by his endocrinologist.

Discussion

The white dyschromia that characterizes leukonychia can be further classified into true, apparent and pseudo as shown in Figure 3. Pseudoleukonychia is usually identified as a superficial fungal infection by the friability of the nail due to keratin debris and fungal elements. By firmly pressing on the nail, the white discoloration fades in cases of apparent leukonychia, clinically distinguishing it from true leukonychia. In true leukonychia, the discoloration grows out with the nail, a process that affords the physician an opportunity to estimate the date of the offending insult. Each millimeter of growth represents approximately 10 days.³

As shown in Figure 3, true leukonychia is further categorized by the extent of nail involvement into total, subtotal, and partial leukonychia. Partial leukonychia is a common nail finding, and the main subdivisions include punctate,

transverse/striate (relatively common), and longitudinal, among other less common forms.⁴ The discovery of transverse leukonychia should warrant further investigation because, although typically caused by trauma, in some instances this clinical sign may represent a serious and acute underlying illness.^{5,6}

Generally, the horizontal white bands characteristic of transverse leukonychia present differently based on their cause. Common exogenous causes include intense manicuring or topical application of therapeutic and occupationally-derived agents and usually feature bands parallel to the contour of the proximal nail fold. Conversely, endogenous insults typically induce wide arcuate bands that parallel the lunula as the nail grows and transverse the width of the nail plate.^{4,7} Although these characteristics are typical, unorthodox cases have been reported. For example, traumatic transverse leukonychia has presented as wide arcuate bands with the same contour as the lunula⁸ and endogenous transverse leukonychia has featured lines that parallel the contour of the proximal nail fold and do not transverse the width of the nail plate.⁹ Although our patient's nail findings are not the classic presentation of endogenous transverse leukonychia, they are likely related to recurrence of hyperparathyroidism due to the synchronicity of the nail findings, absence of trauma in his history and involvement of multiple nails.

Our case of transverse leukonychia underscores the potential for the minimally invasive gross nail examination to reflect internal functional status. Here we report a case due to a relatively mild asymptomatic condition of hyperparathyroidism, but in many cases, these findings may represent a more serious process that could be detected by simple nail examination.

Figures

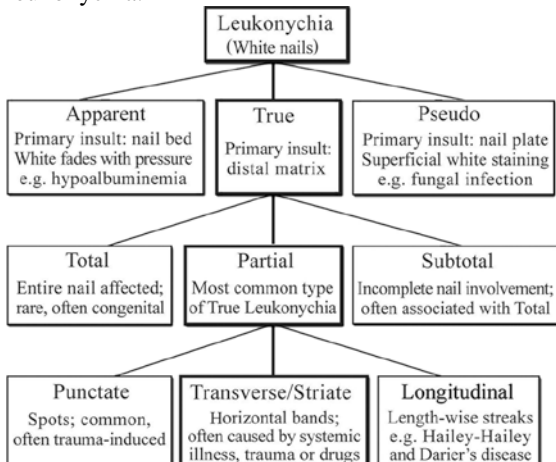
Figure 1: Transverse Leukonychia. This image shows multiple horizontal white lines with convex curvature on his second through fifth fingernails of the right hand.

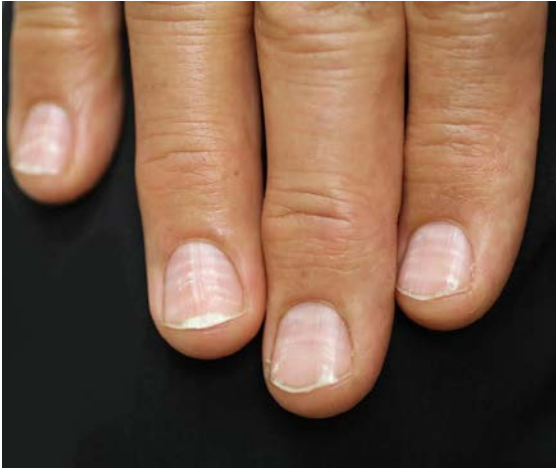

Figure 2: Transverse Leukonychia. This image shows multiple horizontal white lines with convex curvature on his second through fifth fingernails of the left hand.

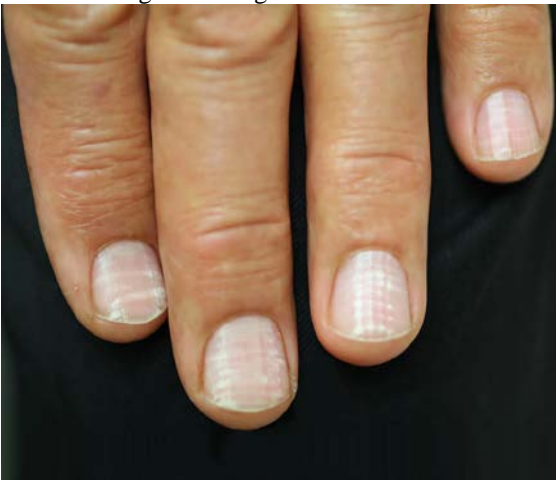

Figure 3: Leukonychia. Clinical categorization of leukonychia.



REFERENCES

1. **Silverberg SJ, Shane E, Dempster DW, Bilezikian JP.** The effects of vitamin D insufficiency in patients with primary hyperparathyroidism. *Am J Med.* 1999 Dec;107(6):561-7. PubMed PMID: 10625024.
2. **Tan AU Jr, Levine BS, Mazess RB, Kylo DM, Bishop CW, Knutson JC, Kleinman KS, Coburn JW.** Effective suppression of parathyroid hormone by 1 alpha-hydroxy-vitamin D2 in hemodialysis patients with moderate to severe secondary hyperparathyroidism. *Kidney Int.* 1997 Jan;51(1):317-23. PubMed PMID:8995749.
3. **Dawber R.** Fingernail growth in normal and psoriatic subjects. *Br J Dermatol.* 1970 May;82(5):454-7. PubMed PMID: 5431550.
4. **Baran R, Dawber R, Haneke E, Tosti A.** Text atlas of nail disorders: Taylor and Francis; 1996.
5. **Foti C, Cassano N, Palmieri VO, Portincasa P, Conserva A, Lamuraglia M, Palasciano G, Vena GA.** Transverse leukonychia in severe hypocalcemia. *Eur J Dermatol.* 2004 Jan-Feb;14(1):67-8. PubMed PMID: 14965801.
6. **Hudson JB, Dennis AJ Jr.** Transverse white lines in the fingernails after acute and chronic renal failure. *Arch Intern Med.* 1966 Feb;117(2):276-9. PubMed PMID:5901563.
7. **Daniel CR.** Diagnosis of onychomycosis and other nail disorders. 1st ed: Springer; 1995.
8. **Baran R, Perrin C.** Transverse leukonychia of toenails due to repeated microtrauma. *Br J Dermatol.* 1995 Aug;133(2):267-9. PubMed PMID: 7547396.
9. **Zaun H.** Leukonychias. *Semin Dermatol.* 1991 Mar;10(1):17-20. Review. PubMed PMID: 2018713.

Submitted April 20, 2015