

CLINICAL VIGNETTE

Occult Vision Deficit in Elderly Patients with Cataracts

Maria P. Hamilton, M.D.

Introduction

A cataract, a clouding of the crystalline lens of the eye, is the most prevalent cause of visual impairment and blindness in the world.¹ While the specific categorization and treatment of cataract is within the domain of ophthalmology, it is often the primary care physician to whom the patient first presents. While a visual complaint may bring the patient in to see his or her primary care physician, the presentation may not have an obvious vision component and may often suggest other diagnoses, common in the elderly population, which require investigation to rule out serious, urgent, and potentially life-threatening conditions (e.g., CVA and MI). Once these entities are ruled out, the primary care physician, with some simple additions to the history and physical exam, can often diagnose cataracts. The physician can then refer the patient to ophthalmology, where cataract surgery can restore significant quality of life to patients who often believe their vision deficits are just an expected part of the aging process.

Case Report

A 72-year-old female artist with hypertension, hyperlipidemia, and benign paroxysmal positional vertigo presented to her primary physician with left knee pain after falling 1 week prior to presentation. Per history, the patient tripped on a rug on her way to the bathroom at night. She landed on her right knee and scraped her right elbow. There was no previous history of falls, no associated chest pain, shortness of breath, dizziness, or loss of balance prior to the fall. She reported good control of her vertigo and avoids abrupt movement when rising from bed at night. She also maintains adequate hydration and nutrition during the day. She has been to physical therapy for fall prevention.

Physical examination revealed a healthy appearing elderly female in no acute distress. Head, neck, cardiovascular, lungs, abdominal, and neurological exams were normal. Dix-Hallpike maneuver was normal. Right knee exam revealed minimal excoriation and effusion, but otherwise no evidence of instability. Blood pressure was 132/82, heart rate was 74, and respiratory rate was 12. Electrocardiogram showed HR 78, normal sinus rhythm, and no acute ischemic changes. Laboratory results including CBC, CMP, BNP, TSH, and hemoglobin A1c were within normal range.

The patient was questioned further about her vision. She initially denied any difficulties including with night vision. When asked if she drives at night, the patient replied that she does not. When asked why, the patient replied that she has

trouble seeing street signs and, in fact, recently scraped her front fender when pulling the car into her garage at night. The patient used to wear only reading glasses but now finds she does not always need them. Distance visual acuity without correction was measured as 20/40 in each eye. Direct ophthalmoscopy revealed an asymmetric red reflex with spoke-like defects in both eyes.

The patient was referred to ophthalmology where she was found to have visually significant cataracts in both eyes. Her refraction revealed myopia of -2.00 diopters in the right eye and -1.50 diopters in the left eye. Sequential cataract surgery with intraocular lens implantation was carried out in each eye. The patient returned to her primary care physician and reported a significant improvement in her ability to drive, read, cook, apply make-up, and clean the house. Most notably, she feels like a “re-born artist” as she can now appreciate subtleties of color, which she has been unable to appreciate for the past 20 years. Uncorrected visual acuity was measured as 20/20 in each eye.

Discussion

Ninety percent of blindness (visual acuity < 20/200) in developed countries can be attributed to cataracts. Among Americans, a visually significant cataract (visual acuity < 20/40) is present in approximately 20.0% of those aged 60-69 years, 42.8% of those aged 70-79 years, and 68.3% of those aged greater than 80 years.¹ In California, there are more than 2.5 million people over the age of 40 with cataracts.² The Baby Boomer generation, individuals born between the years 1946 and 1964, began reaching 65 years old in 2011. Between the years 2010 and 2030, the U.S. population over 60 will increase from 60 million to 90 million, a 50% increase (Figure 1).³ Cataract surgery, the most common surgical procedure performed in the U.S., is also the most successful with a complication rate of less than 1%. Recent innovations have produced advanced intraocular lens implants that not only provide excellent visual acuity but also allow for spectacle independence, significantly improving a patient’s quality of life.

The most common types of cataracts are nuclear sclerosis, cortical, and posterior subcapsular cataracts. Nuclear sclerosis, overall the most common type of cataract, is the age-related gradual yellowing and hardening of the lens nucleus (Figure 2). Progression of nuclear sclerosis is gradual but ubiquitous, occurring earlier in patients with high myopia. The clinical

appearance is often seen as a central “oil droplet” darkening in the red reflex with direct ophthalmoscopy (Figure 3). Nuclear sclerotic changes often lead to a myopic shift, an increase in nearsightedness known as “second sight”. Patients with nuclear sclerosis may often report that they can read without reading glasses for the first time in years. Upon questioning, these patients will often complain of general difficulty with night driving and, in particular, seeing street signs.

Cortical cataracts develop in the outer layers of the lens, resulting in spoke-like opacities extending from the periphery towards the center of the lens (Figure 4A). Often seen in patients with diabetes, the rate of progression of cortical cataracts varies greatly but can be rapid, occasionally leading to a “mature” cortical cataract resulting in opalescent whitening of the lens and severe loss of vision. The clinical appearance of a cortical cataract is dark spoke-like shadows extending from the periphery to the center of the lens, disrupting the red reflex with direct ophthalmoscopy (Figure 4B). Patients with cortical cataracts typically will complain of significant glare from focal light sources (e.g., headlights, street lights, and traffic lights). Patients may also complain of double vision from only one eye (monocular diplopia).

Posterior subcapsular cataract (PSC) manifests as a plaque-like opacity on the back surface of the lens, typically along the visual axis (Figure 5A). While PSC cataracts are commonly seen in the aging process of the lens, they can often be seen in younger patients; occur as a result of trauma, systemic, topical, or intraocular corticosteroid use; be caused by inflammation or exposure to ionizing radiation; and can be related to alcoholism. The patient with PSC cataract often complains of glare and poor vision under bright lighting conditions. Near vision tends to be reduced more than distance vision. Some patients experience monocular diplopia. The clinical appearance is a disruption of the central portion of the red reflex seen with direct ophthalmoscopy (Figure 5B).

Clinical Pearls for Cataract Diagnosis

- 1. Ask elderly patients about night driving.** The patient may not acknowledge they have problems with driving but will often admit they do not drive at night. When questioned further, they will acknowledge they just do not feel comfortable.
- 2. Ask about recent changes in glasses prescription.** Cataract formation and progression often lead to increasing nearsightedness and changes in astigmatism. This can lead to frequent updates to glasses prescriptions, which can be costly and very frustrating to patients.
- 3. Ask about “second sight”.** Particularly with nuclear sclerotic cataracts, patients who previously needed reading glasses may report that they can now read without glasses. This is due to the increasing nearsightedness that occurs with nuclear sclerosis.
- 4. Look for disruption of the red reflex on direct ophthalmoscopy.** Each type of cataract creates a characteristic disruption of what should be a uniform red reflex on direct ophthalmoscopy.

Conclusion

Elderly patients presenting to their primary care physician will often neglect to mention vision deficits, either because they have other complaints, as in this case report, or because they believe declining vision is a normal part of the ageing process. While it is of paramount importance to rule out life-threatening disease states, cataracts are often a relevant diagnosis that can be diagnosed with relative ease by asking some key questions during history taking and by observing the red reflex of the eye during direct ophthalmoscopy. A referral for cataract surgery can be a life-changing experience for the patient.

Images

Figure 1. Historic and projected U.S. 60+ population in millions. *Modified figure from www.census.gov*

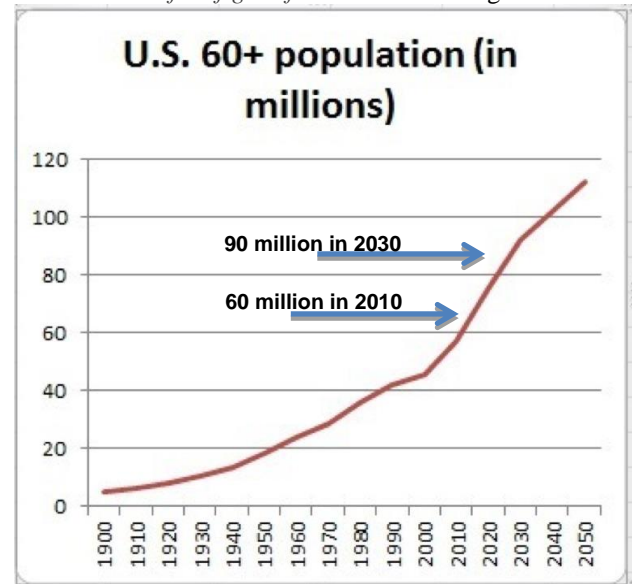


Figure 2. Increasing yellow-to-brown coloration of the human lens from 6 months (A) through 8 years (B), 12 years (C), 25 years (D), 47 years (E), 60 years (F), 70 years (G), 82 years (H) and 91 years (I). *American Academy of Ophthalmology 2015-2016 Basic and Clinical Science Course, Section 11: Lens and Cataract. Chapter 4, Figure 4-1*

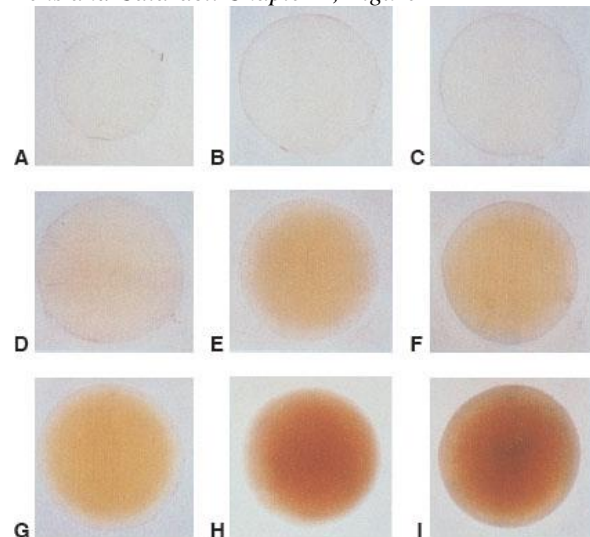


Figure 3A-C. Clinical view of nuclear sclerotic cataract. Note the brown coloration in center of lens seen through dilated pupil. **3B:** Red reflex view of nuclear sclerotic cataract using direct ophthalmoscopy. Note darkening at center of red reflex. **3C:** Schematic of human crystalline lens with nuclear sclerotic cataract showing position of lens nucleus at center of lens. *Modified from American Academy of Ophthalmology 2015-2016 Basic and Clinical Science Course, Section 11: Lens and Cataract. Chapter 4, Figure 4-2.*

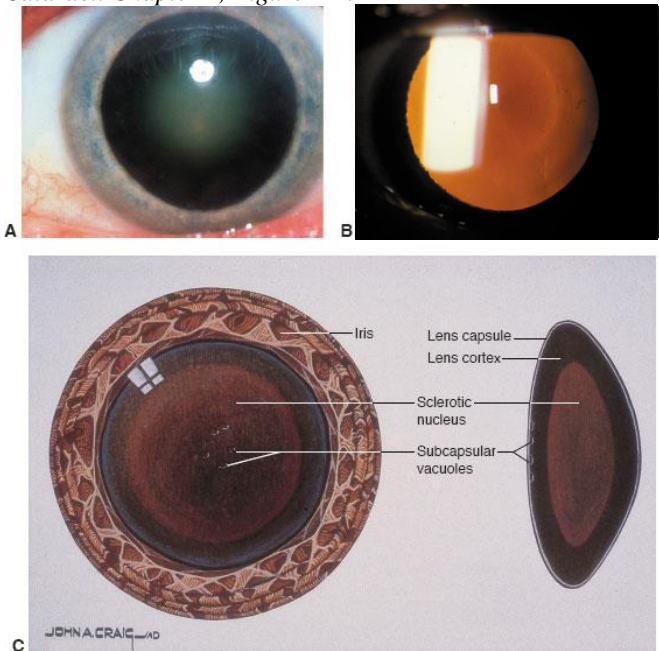


Figure 4A. Schematic of human crystalline lens with a cortical cataract. Note the wedge-like opacities, located in the peripheral region of the lens called the cortex, extending from the periphery toward the center.

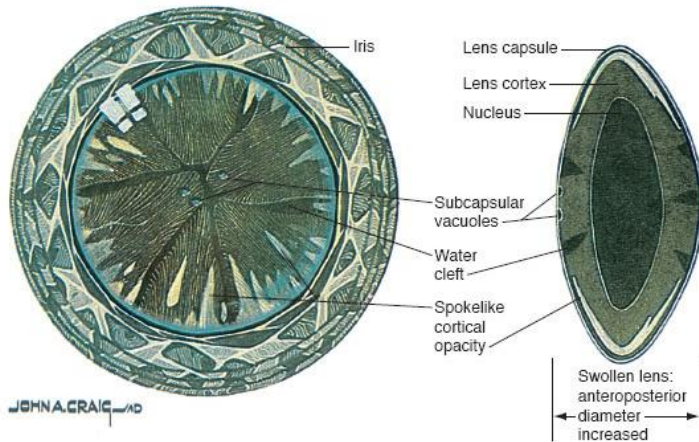


Figure 4B. Red reflex view of cortical cataract using direct ophthalmoscopy. Note dark spoke-like shadows extending from the periphery toward the center. *Modified from American Academy of Ophthalmology 2015-2016 Basic and Clinical Science Course, Section 11: Lens and Cataract. Chapter 4, Figure 4-4.*

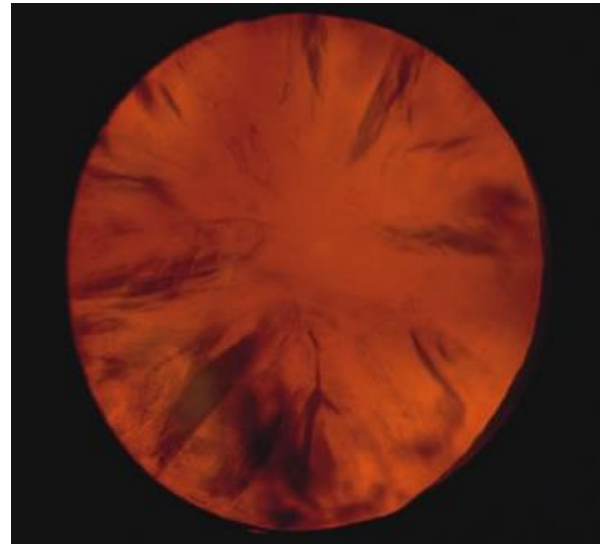


Figure 5A. Schematic of posterior subcapsular cataract. Note granular deposits in the center of the posterior surface of the lens.

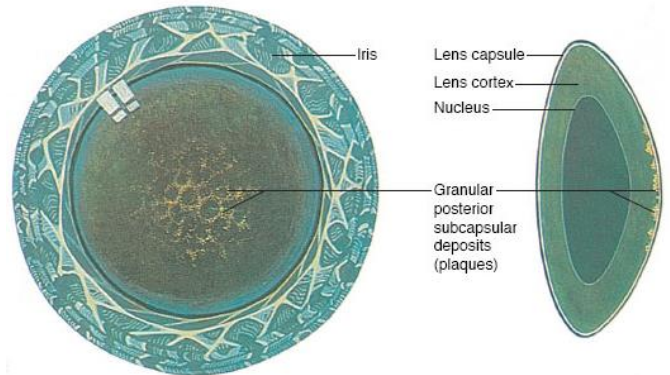

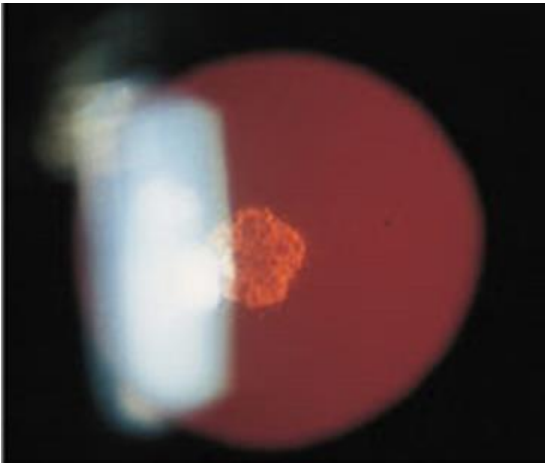


Figure 5B. Red reflex view of posterior subcapsular cataract using direct ophthalmoscopy. Note disruption of red reflex near the center. *Modified from American Academy of Ophthalmology 2015-2016 Basic and Clinical Science Course, Section 11: Lens and Cataract. Chapter 4, Figure 4-8.*





REFERENCES

1. **Thompson J, Lakhani N.** Cataracts. *Prim Care.* 2015 Sep;42(3):409-23. doi: 10.1016/j.pop.2015.05.012. Review. PubMed PMID: 26319346.
2. <http://www.visionproblemsus.org/>
3. <http://www.census.gov/>

Submitted September 10, 2015