

## Clinical Vignette

---

# Sporadic Burkitt's Lymphoma

---

Mikhail Kovshilovsky, Jennifer Goldstein, M.D., Robert Deiss, M.D., Kuo-Chiang Lian, M.D.

### ***Introduction***

Burkitt's lymphoma is a highly aggressive B-cell neoplasm associated with translocation of the c-MYC oncogene. It is a non-Hodgkin's type lymphoma which consists of endemic, sporadic, and immunodeficiency-associated subtypes. This rare condition occurs most commonly among young male patients.

Burkitt's lymphoma is diagnosed by characteristic histologic appearance and responds well to chemotherapy.<sup>1, 2</sup>

### ***Case Presentation***

A 20-year-old Iranian man without significant past medical history presented to the emergency department complaining of two and a half weeks of intermittent burning and sharp abdominal pain. Two weeks prior

at another emergency department he was diagnosed with gastritis and discharged home. Subsequent to this his primary doctor diagnosed him with colitis and prescribed trimethoprim/sulfamethoxazole and dicyclomine. However, the patient reported no relief of symptoms from this treatment.

One week prior to presentation the pain became more diffuse. The pain also lasted longer and worsened with food. He reported nausea and one episode of self-induced vomiting, which provided some relief. He had been constipated for the week prior, having alternating watery or hard bowel movements every 2-3 days. There was also no relief of pain with bowel movements. No blood was seen in emesis or stool. The pain acutely worsened the night prior to presentation, prompting the present visit to the emergency department. Review of systems was otherwise unremarkable; notably, the

patient did not have any fevers, chills, night sweats, weight loss, oral ulcers, cough, shortness of breath, diarrhea, dysuria, muscle pain, weakness, or easy bruising/bleeding.

Physical examination at the time of admission was noteworthy for a soft, diffusely tender abdomen without rebound or guarding. Bowel sounds were normoactive and splenomegaly was present. A single tender 1cm left inguinal lymph node was noted to be matted and mobile.

Routine complete blood count, chemistry panel, lipase, coagulation times and urinalysis were all within normal limits. Human

Immunodeficiency Virus (HIV) antibody test was negative and serology for Epstein-Barr Virus (EBV) revealed prior exposure and immunity. A contrast-enhanced CT of the abdomen and pelvis revealed a 9x5cm cecal mass, omental carcinomatosis, multiple enlarged abdominal and portocaval lymph nodes, and a hyperdense lesion in the liver (Figure 1). A biopsy of the mass revealed a monotypic B-cell malignancy and a characteristic starry sky appearance consistent with Burkitt's lymphoma. Immunohistochemistry showed a high fraction

of cells staining for Ki-67 and FISH revealed c-MYC positivity (Figure 2).

Further CT imaging obtained for staging revealed intrathoracic lymphadenopathy, and a lumbar puncture did not reveal any Central Nervous System (CNS) disease. Treatment was initiated with CODOX-M (intravenous cyclophosphamide, vincristine, doxorubicin, methotrexate with cytarabine intrathecal prophylaxis) alternating with IVAC (intravenous ifosfamide, etoposide, and cytarabine) chemotherapy. The patient subsequently responded well to several cycles of chemotherapy and exhibited a complete response with no residual clinical and radiologic evidence of disease after four cycles of chemotherapy (Figure 3).

### ***Discussion***

Burkitt's lymphoma was first described by surgeon Denis Parsons Burkitt when he was working in central Africa in the 1950's. He noticed children with masses involving the face, upper and lower jaws, and the abdomen.<sup>3</sup> While the malignancy was initially thought to be a

sarcoma, it was later recognized to be a lymphoma. In 1961, Burkitt shared samples with Michael Anthony Epstein, an experimental pathologist. Subsequently, Epstein and his colleagues described the involvement of Epstein-Barr virus (EBV) in the pathogenesis of Burkitt's lymphoma.<sup>4</sup> It has since been discovered that there is a translocation of the c-MYC gene leading to its over-expression and cellular proliferation.<sup>2</sup>

There are three variants of Burkitt's lymphoma: endemic, sporadic, and immunodeficiency-associated. While these are all histologically identical, they have different clinical features. The incidence of Burkitt's lymphoma is estimated to be 50 times greater in Africa than in the United States. The endemic variant is most prevalent in equatorial Africa and produces disease at a younger age, typically between 4-7 years of age.<sup>1</sup> Epstein Barr Virus is found in all cases of endemic variant and the disease usually involves the jaw, other facial bones, and the kidneys. On the other hand, the sporadic variant is more common in the U.S. and Western Europe. The endemic and sporadic variants are

most common among children, with males being affected more than females by 3-4:1. With about 2-3 cases per million per year, the sporadic variant mostly affects extranodal sites, with the abdomen being most commonly affected as in our case above.<sup>5</sup> The immunodeficiency type is often discovered in the setting of HIV. However, it is frequently seen in patients with CD4 counts greater than 200 cells/ $\mu$ L and interestingly, the rate observed in HIV patients has not decreased with Highly Active Antiretroviral Therapy (HAART).<sup>1,2</sup>

In sporadic cases patients will often present with rapidly growing masses. This results in abdominal pain, nausea and vomiting, bowel obstruction, GI bleeding, and syndromes mimicking appendicitis or intussusception. If the mass is large enough, patients may also present with tumor lysis syndrome. Lab studies may reveal elevated lactate dehydrogenase and uric acid.<sup>1,6</sup>

The pathogenesis of Burkitt's lymphoma is related to the translocation of the c-MYC gene on chromosome 8 with one of the Ig genes on

chromosomes 14, 2, or 22. This leads to over-expression of the c-MYC protein and dysregulation of the cell cycle and growth, resulting in a neoplastic counterpart of a subset of normal activated germinal center B cells.<sup>1</sup>

Diagnosis is achieved through pathological evaluation of the involved tissue. Histology reveals monomorphic medium-sized cells with basophilic cytoplasm and high proliferation rates. Classically, a starry-sky is seen as a result of scattered macrophages with ingested nuclear debris with abundant clear cytoplasm amidst a background of malignant cells.<sup>7</sup> Alternatively, the diagnosis can be established through cytogenetics and verification of the c-MYC rearrangement.<sup>2</sup> In children it is important to consider Wilms tumor and neuroblastoma as other differential diagnoses. Other neoplasms that can be difficult to differentiate from Burkitt's lymphoma include lymphoblastic lymphoma, blastic mantle cell lymphoma, and diffuse large B-cell lymphoma.<sup>2</sup>

About 70% of patients present with extensive disease and are at risk of spread to the CNS and

bone marrow.<sup>2</sup> The CNS is involved in 13-17% of adult cases and the bone marrow in 30-38%.<sup>1</sup> Therefore, aggressive chemotherapy and CNS prophylaxis with intrathecal methotrexate is critical to treatment. The initiation of CODOX-M/IVAC presented increased survival, with up to 92% two-year survival for children and adults.<sup>8</sup> However, toxicities such as myelosuppression, mucositis, and neuropathy may be seen with chemotherapy. Additionally, with rapid turnover of tumor cells, tumor lysis syndrome is an important consideration.<sup>2</sup>

### **Conclusion**

Burkitt's lymphoma is a highly-aggressive and rare malignancy accounting for less than 2% of all Non-Hodgkin's lymphomas.<sup>9</sup> The endemic variant is the most common form in Africa, with disease usually affecting the facial bones. The sporadic variant is the most common in the U.S. and commonly presents with an abdominal neoplasm involving the ileocecum and peritoneum.<sup>1,7</sup>

Given the frequent involvement of the abdomen, it is not uncommon for patients to present with symptoms mimicking an acute abdomen. In

cases such as this one, the history and physical may lead to a differential diagnosis other than acute abdomen. With subsequent imaging and biopsy, the diagnosis can be established. This can avoid unnecessary procedures or surgeries and can also expedite the diagnosis and treatment of the underlying disease.

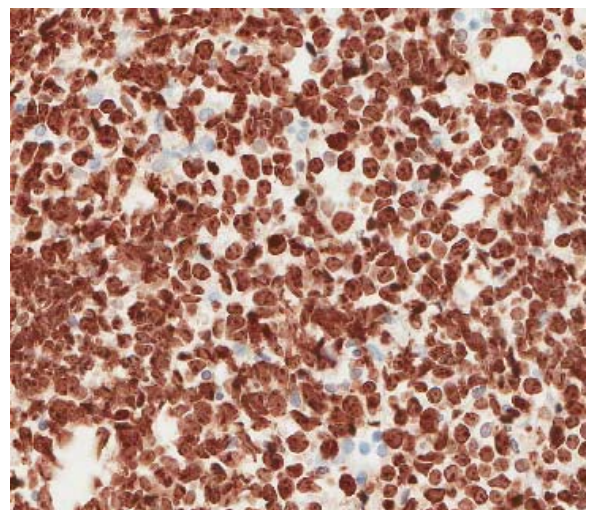
While this is an aggressive tumor, treatment with combination chemotherapy can result in remission and a good overall prognosis.<sup>7, 10</sup>

FIGURE LEGENDS:

Figure 1. Contrast-enhanced CT of the abdomen and pelvis showing 5x9cm cecal mass.

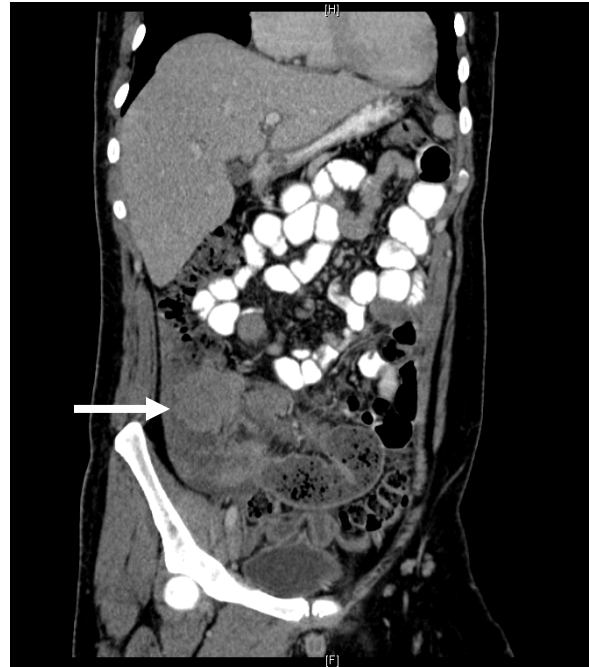

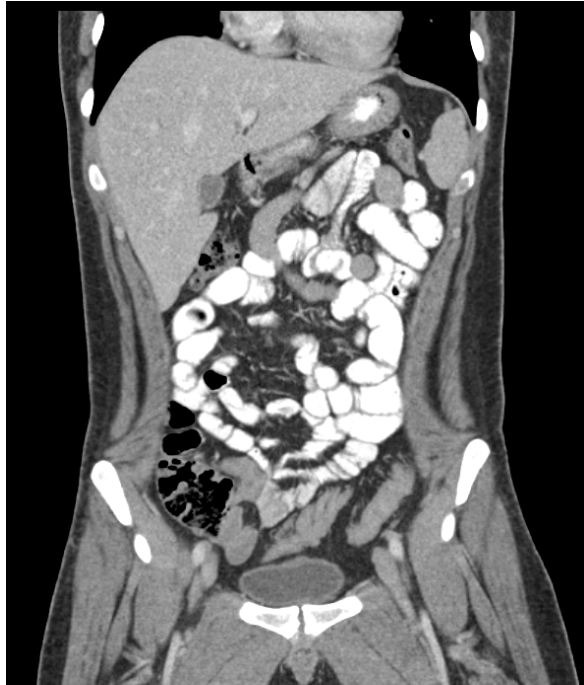Figure 2: Ki-67 stain of cecal mass biopsy showing high proliferation rate of monomorphic medium sized cells.



**Figure 3.** Contrast-enhanced CT of the abdomen and pelvis following four cycles of CODOX/M-IVAC chemotherapy demonstrating complete response.



## References

1. **Blum KA, Lozanski G, Byrd JC.** *Adult Burkitt leukemia and lymphoma.* Blood. 2004 Nov 15;104(10):3009-20. Epub 2004 Jul 20. Review. PubMed PMID: 15265787.
2. **Ferry JA.** *Burkitt's lymphoma: clinicopathologic features and differential diagnosis.* Oncologist. 2006 Apr;11(4):375-83. Review. PubMed PMID: 16614233.
3. **Burkitt D.** *A sarcoma involving the jaws in African children.* Br J Surg. 1958 Nov;46(197):218-23. PubMed PMID: 13628987.
4. **Burkitt DP.** *The discovery of Burkitt's lymphoma.* Cancer. 1983 May 15;51(10):1777-86. PubMed PMID: 6299496.
5. **Parente F, Anderloni A, Greco S, Zerbi P, Bianchi Porro G.** *Ileocecal Burkitt's lymphoma.* Gastroenterology. 2004 Jul;127(1):8, 368. PubMed PMID: 15236165.
6. **Wright DH.** *What is Burkitt's lymphoma?* J Pathol. 1997 Jun;182(2):125-7. PubMed PMID: 9274520.
7. **Kumar V, Fausto N, Abbas A.** *Robbins and Cotran Pathologic Basis of Disease.* 7<sup>th</sup> ed. Philadelphia: Elsevier Saunders; 2005.
8. **Magrath I, Adde M, Shad A, Venzon D, Seibel N, Gootenberg J, Neely J, Arndt C, Nieder M, Jaffe E, Wittes RA, Horak ID.** *Adults and children with small non-cleaved-cell lymphoma have a similar excellent outcome when treated with the same chemotherapy regimen.* J Clin Oncol. 1996 Mar;14(3):925-34. PubMed PMID: 8622041.
9. **Morton LM, Wang SS, Devesa SS, Hartge P, Weisenburger DD, Linet MS.** *Lymphoma incidence patterns by WHO subtype in the United States, 1992-2001.* Blood. 2006 Jan 1;107(1):265-76. Epub 2005 Sep 8. PubMed PMID: 16150940; PubMed Central PMCID: PMC1895348.
10. **Mead GM, Sydes MR, Walewski J, Grigg A, Hatton CS, Pescosta N, Guarnaccia C, Lewis MS, McKendrick J, Stenning SP, Wright D;** UKLG LY06 collaborators. *An international evaluation of CODOX-M and CODOX-M alternating with IVAC in adult Burkitt's lymphoma: results of United Kingdom Lymphoma Group LY06 study.* Ann Oncol. 2002 Aug;13(8):1264-74. Erratum in: Ann Oncol. 2002 Dec;13(12):1961. Norbert, P [corrected to Pescosta, N]. PubMed PMID: 12181251.

Submitted on February 3, 2011